

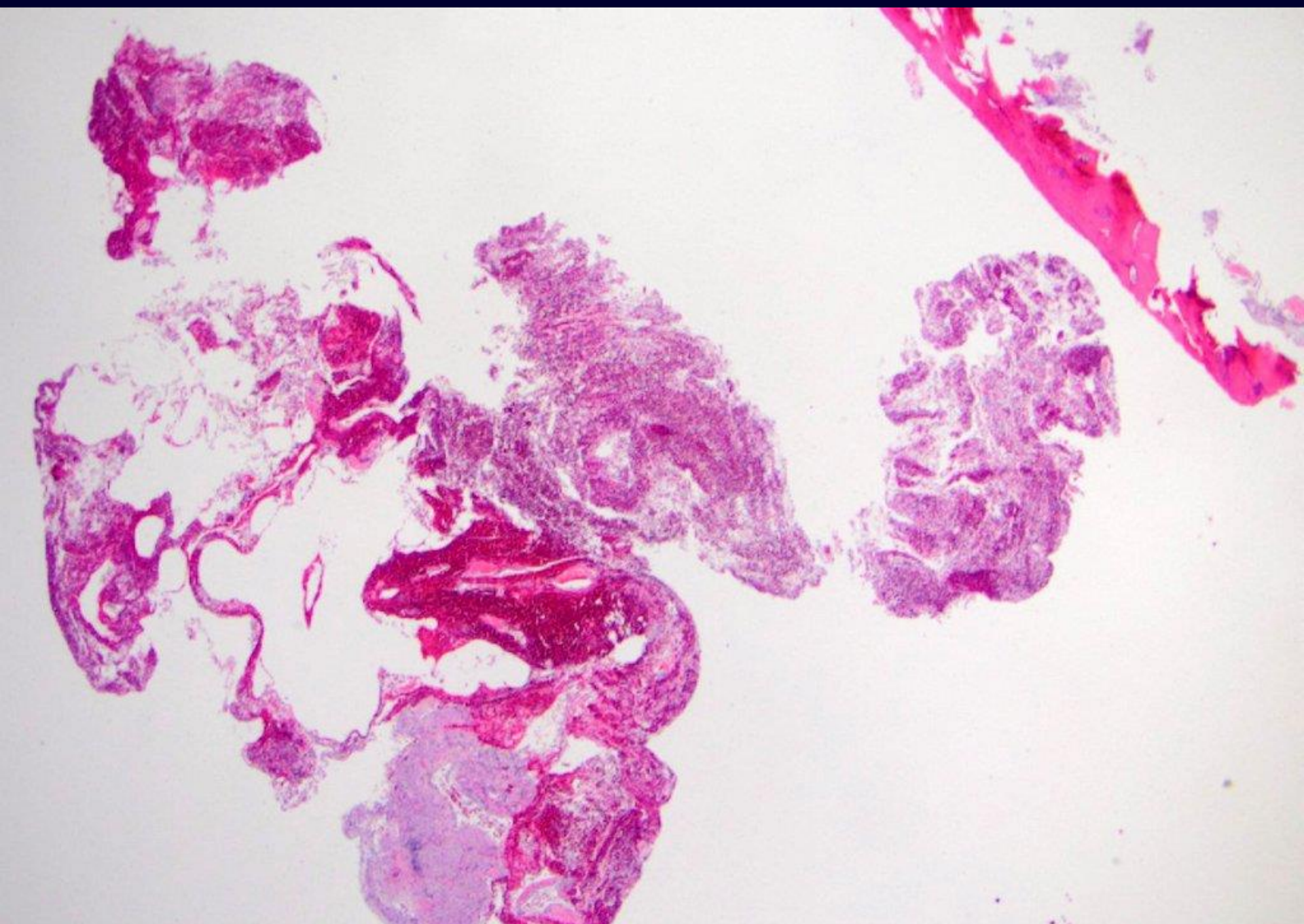
Oral Histopathology

Series 25

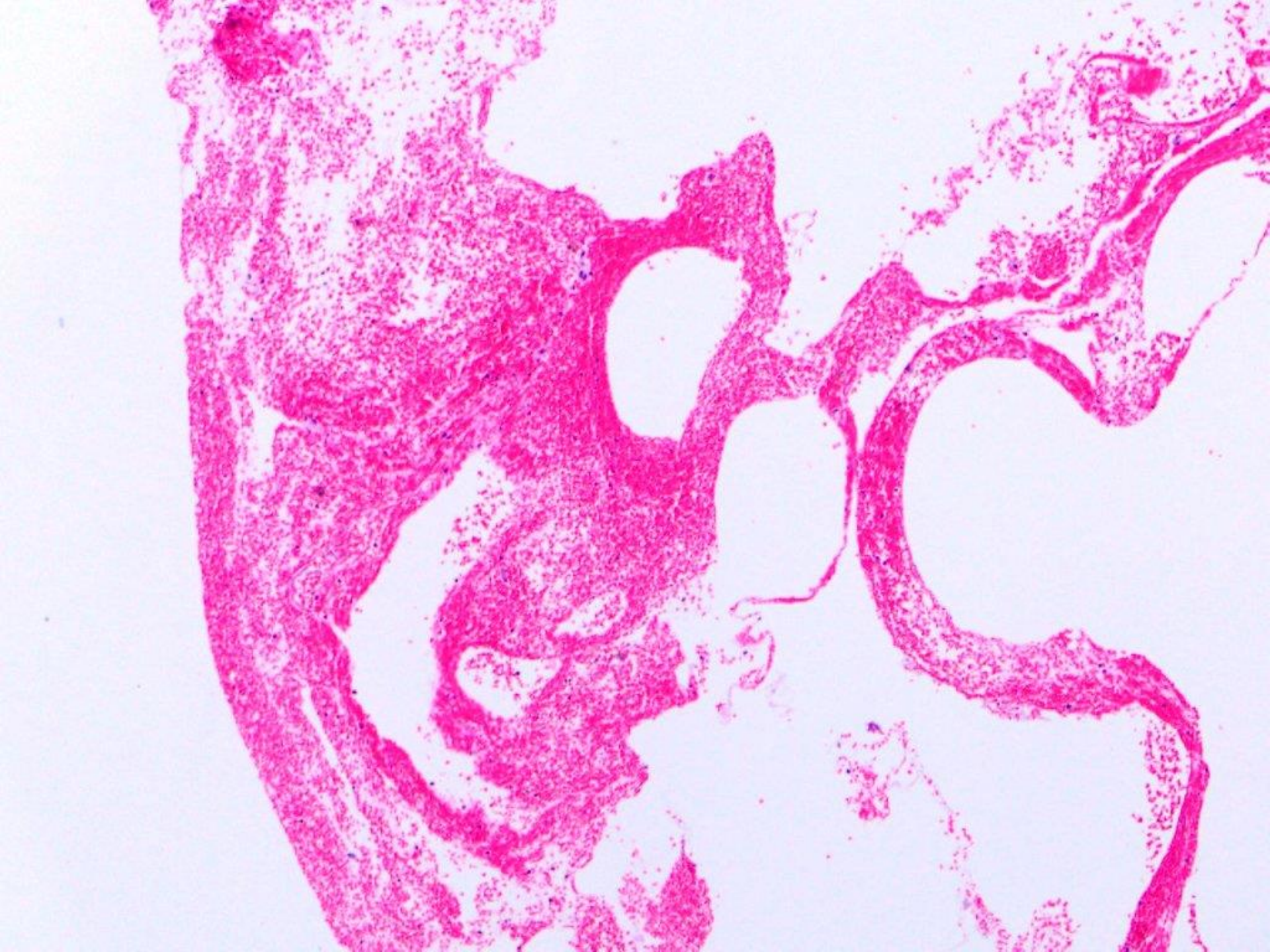
DAVID E. KLINGMAN, DMD

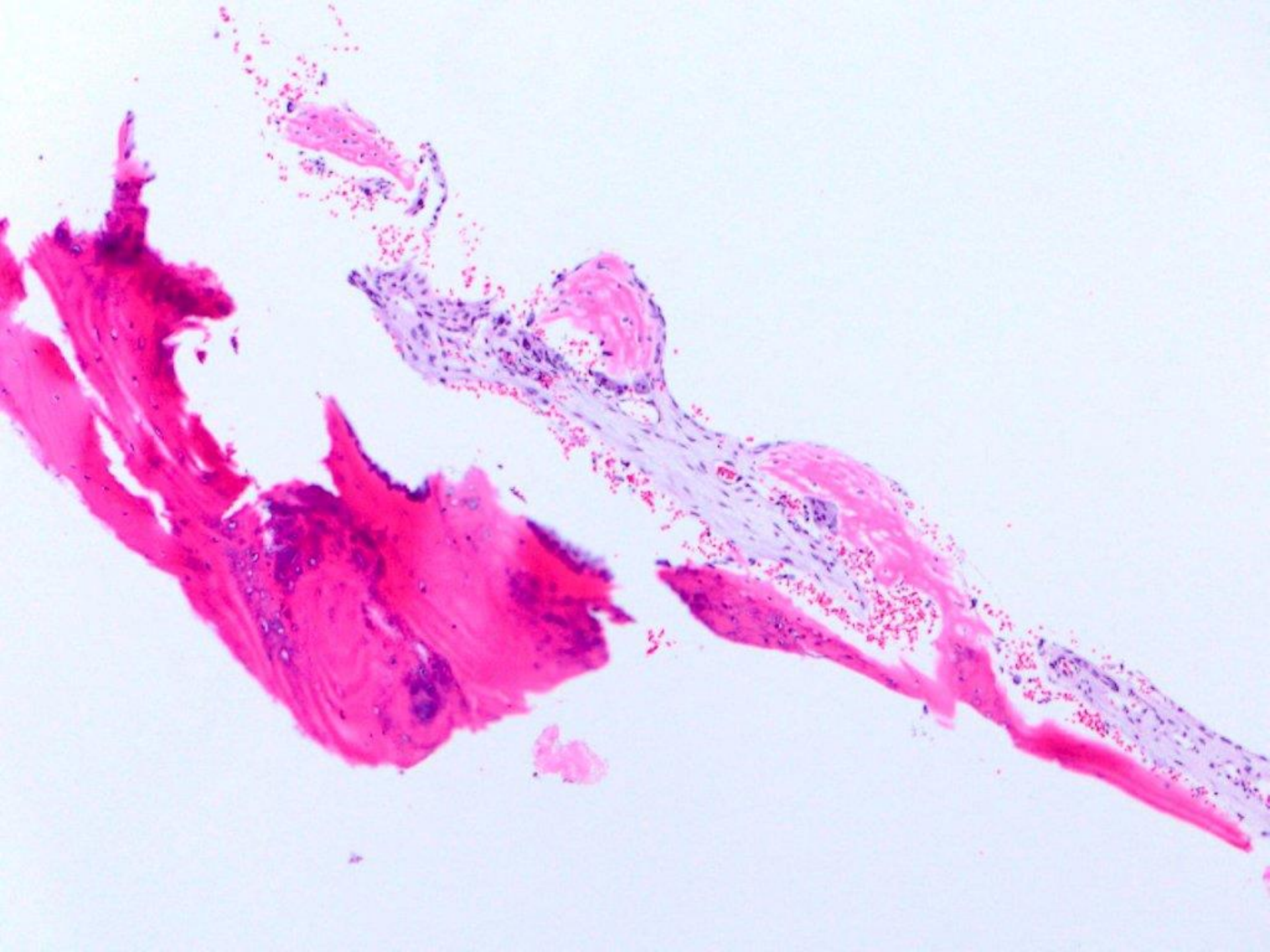
Diplomate, American Board of Oral and Maxillofacial Pathology

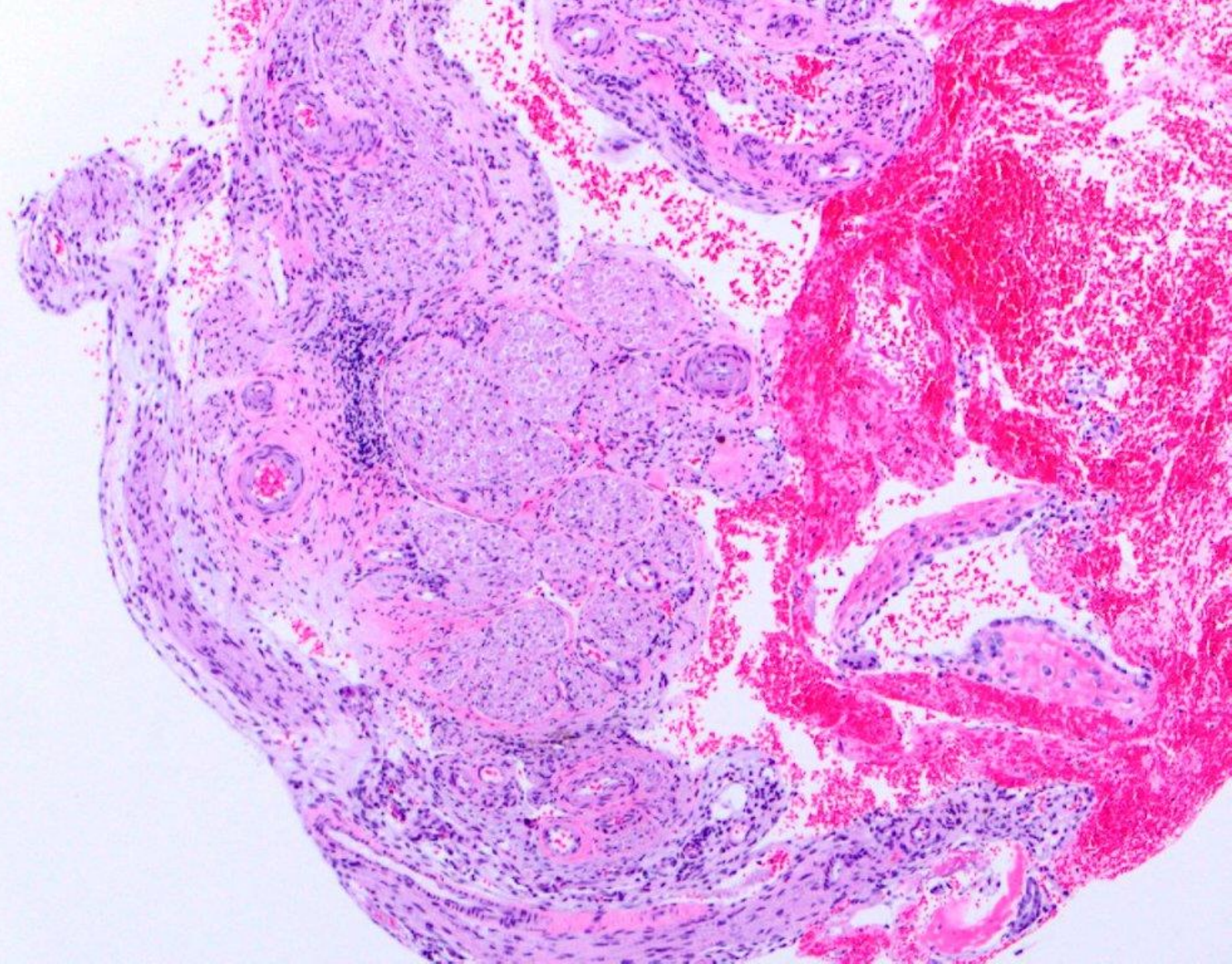
Diplomate, American Board of General Dentistry

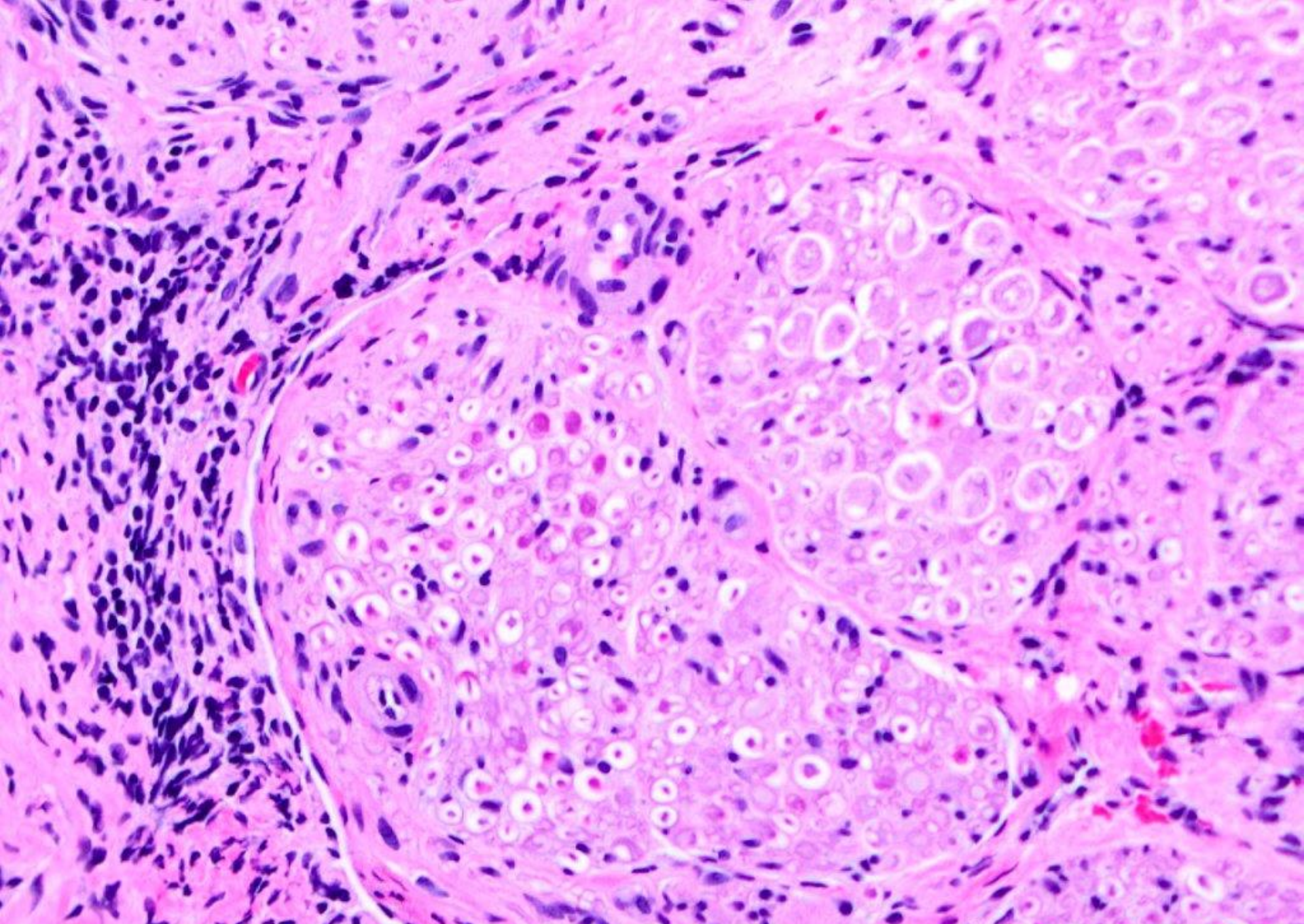


surgeon opened into empty cavity

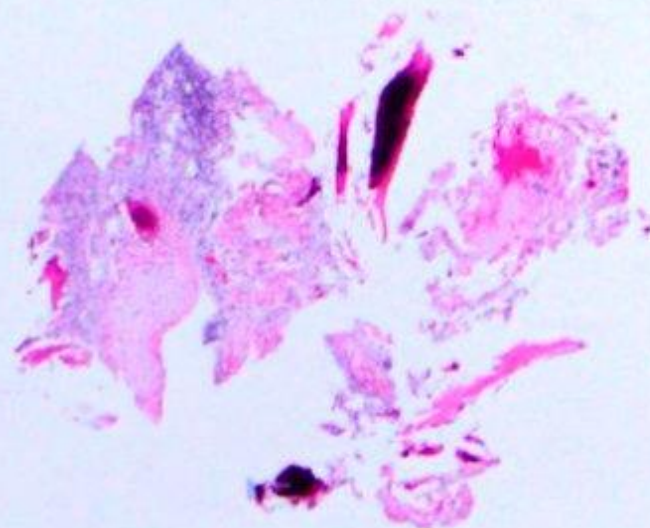
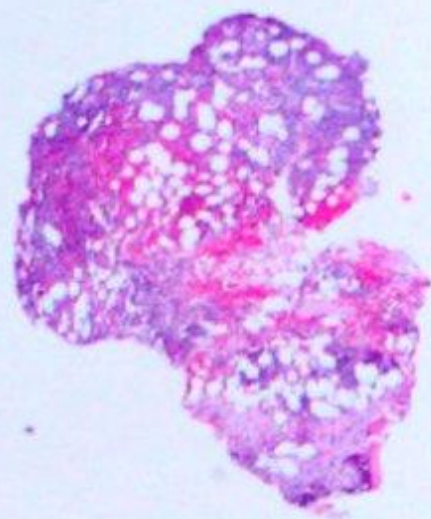


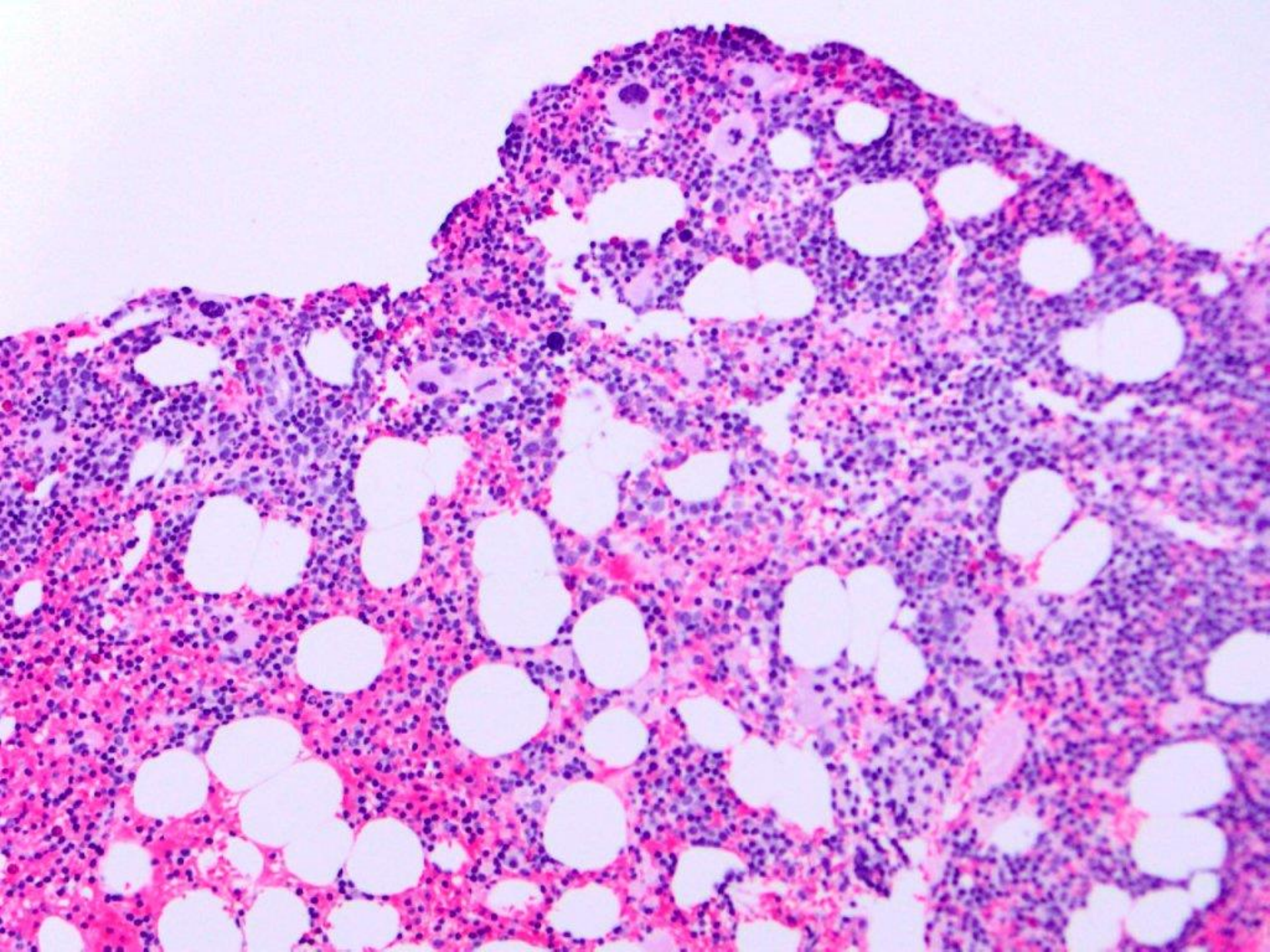


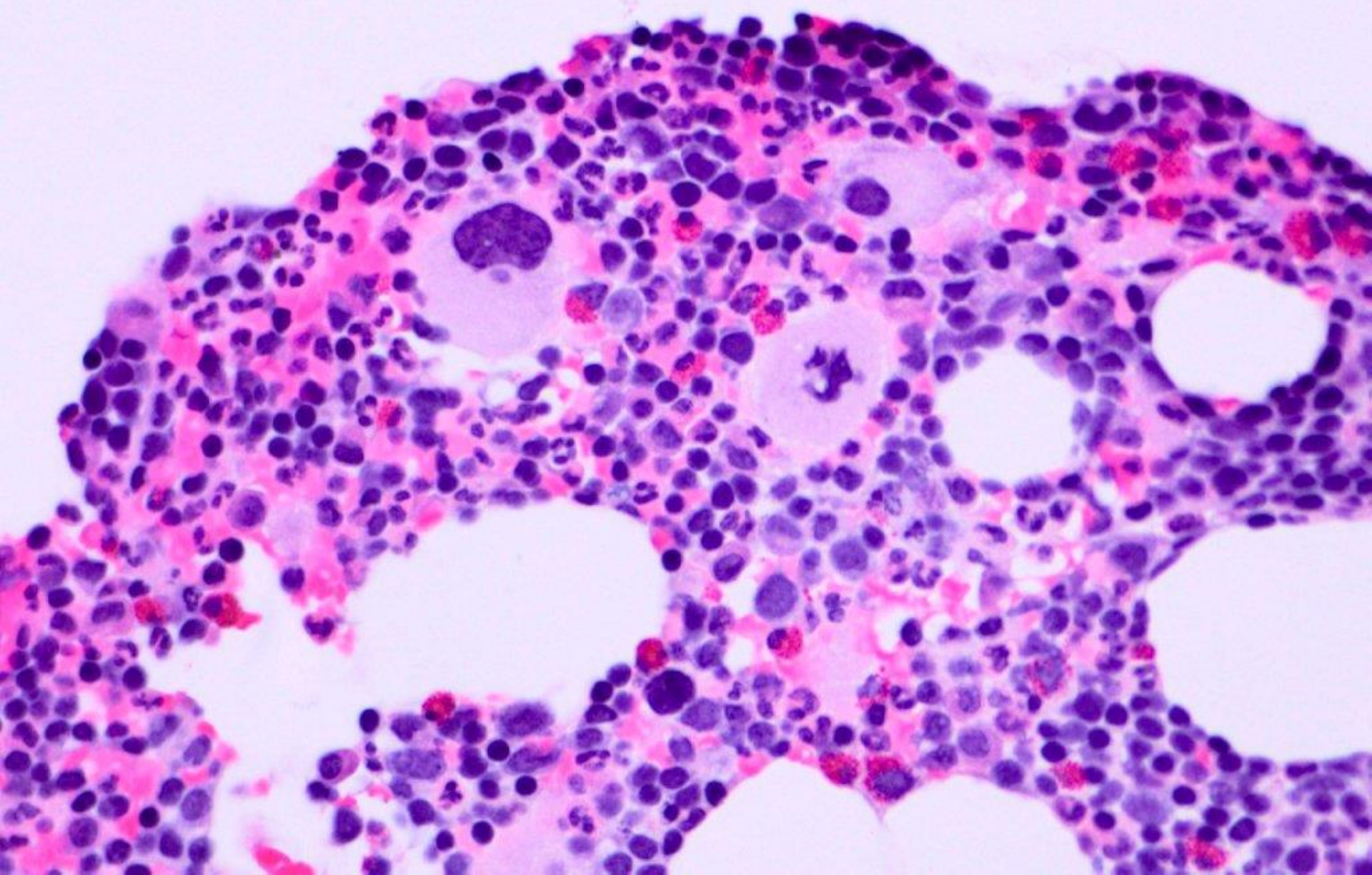


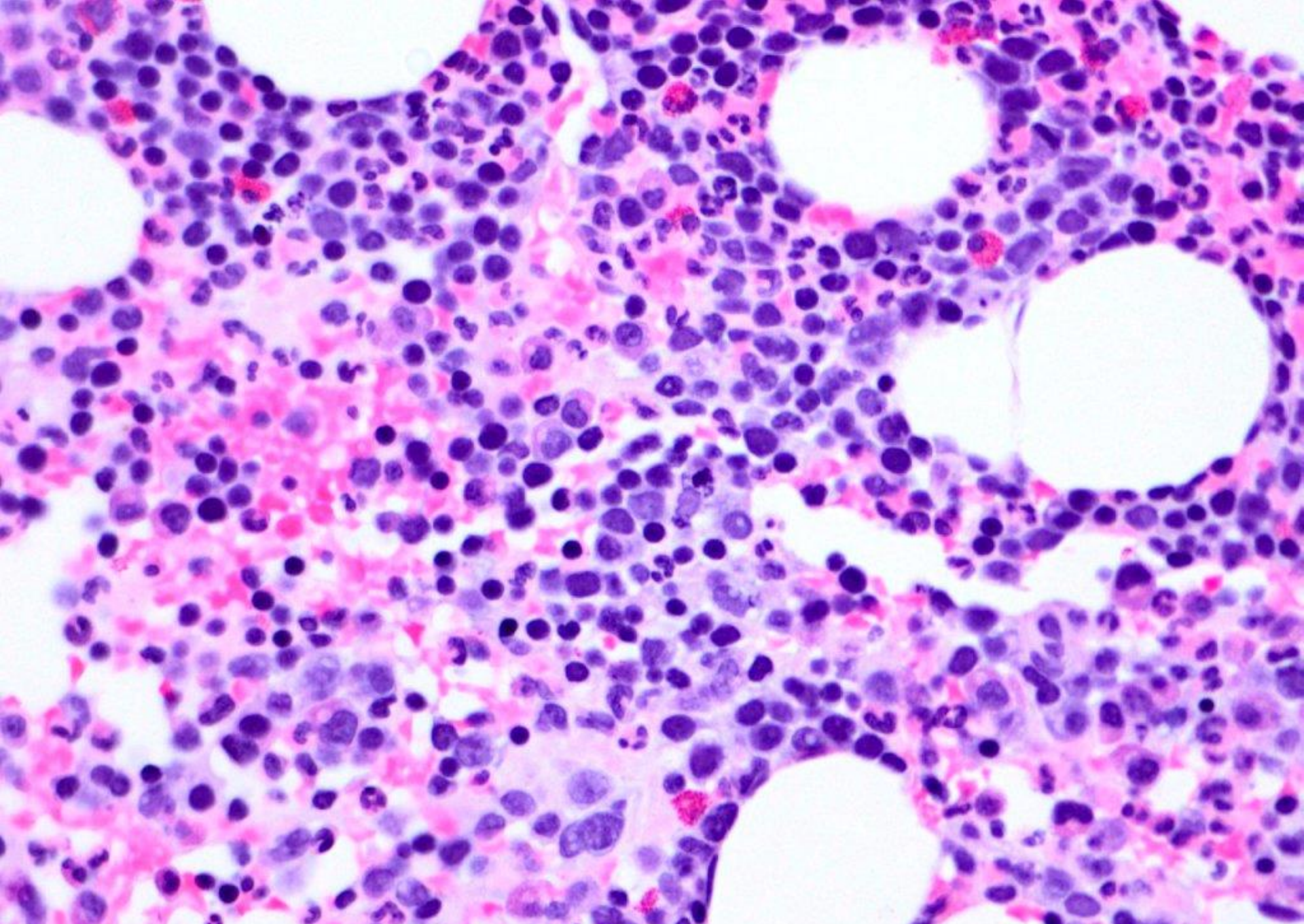


traumatic bone cyst

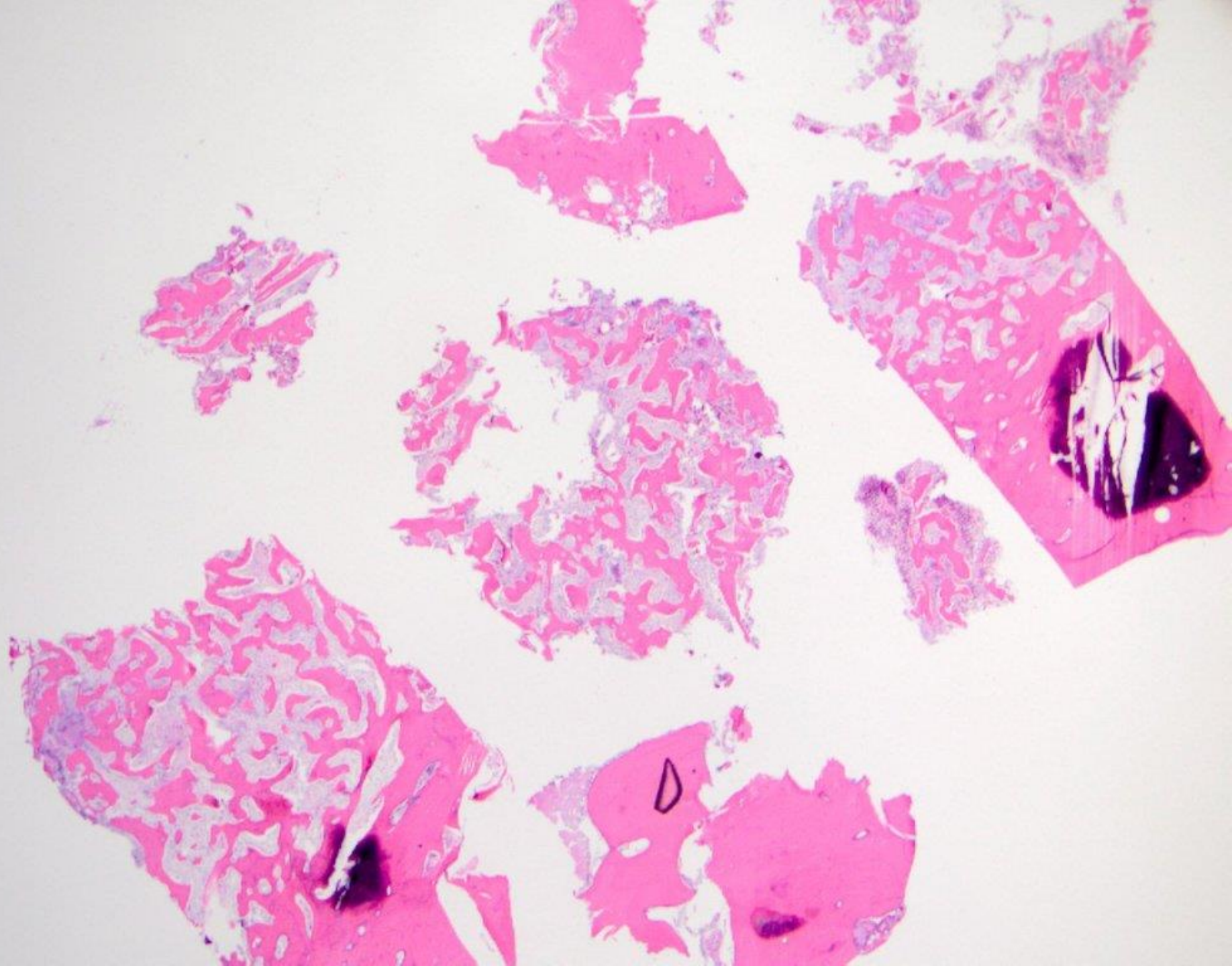


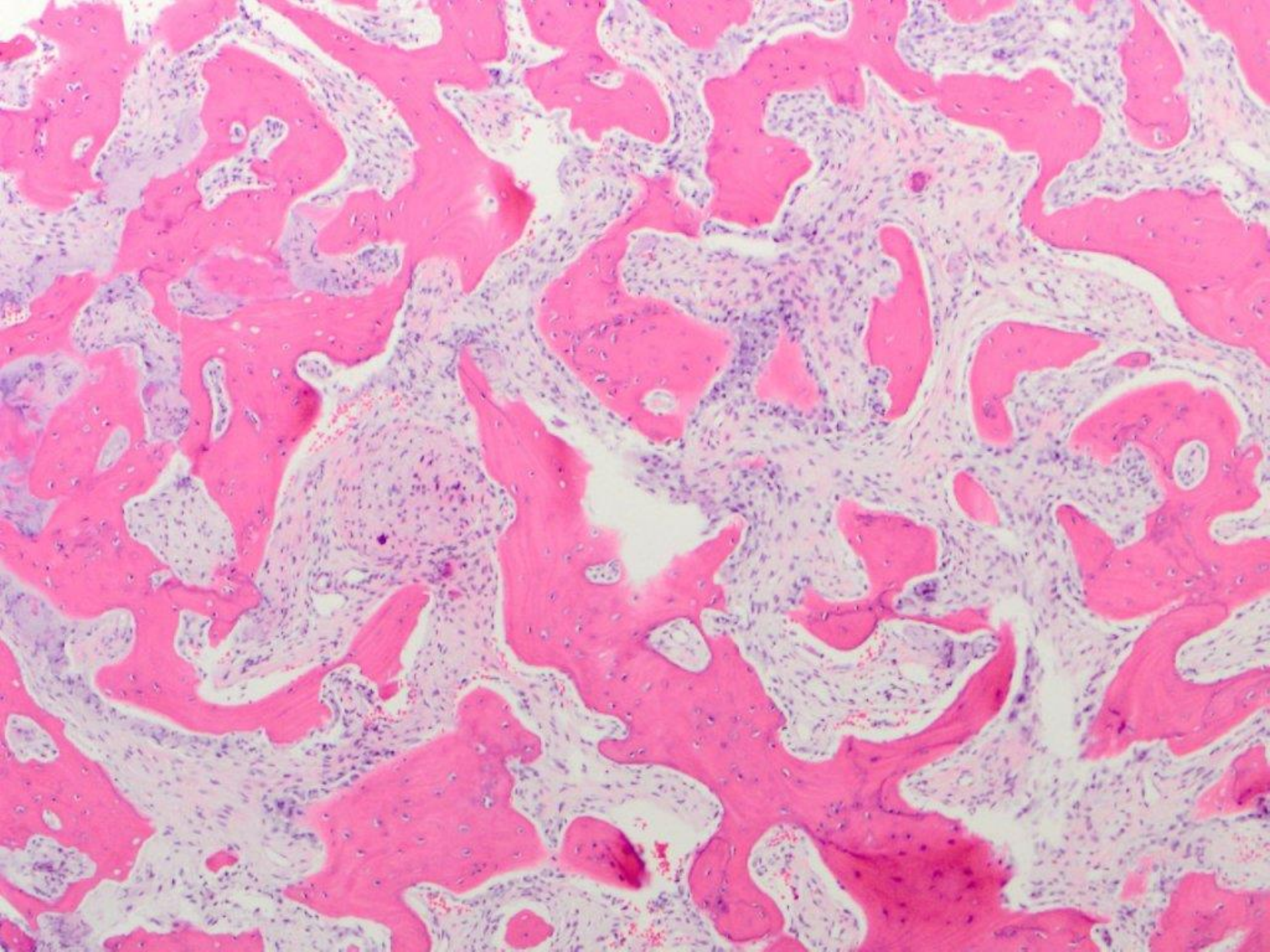


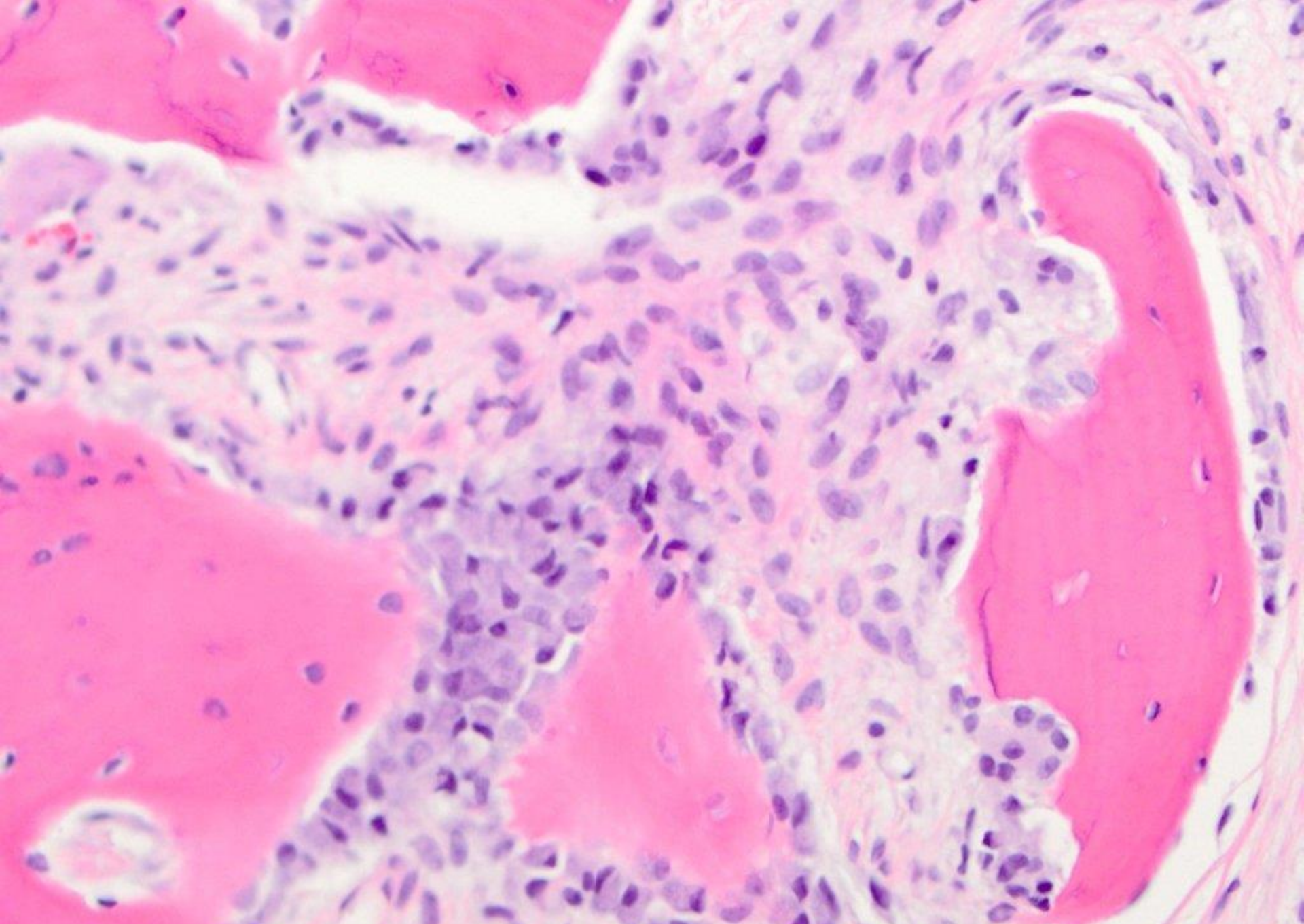




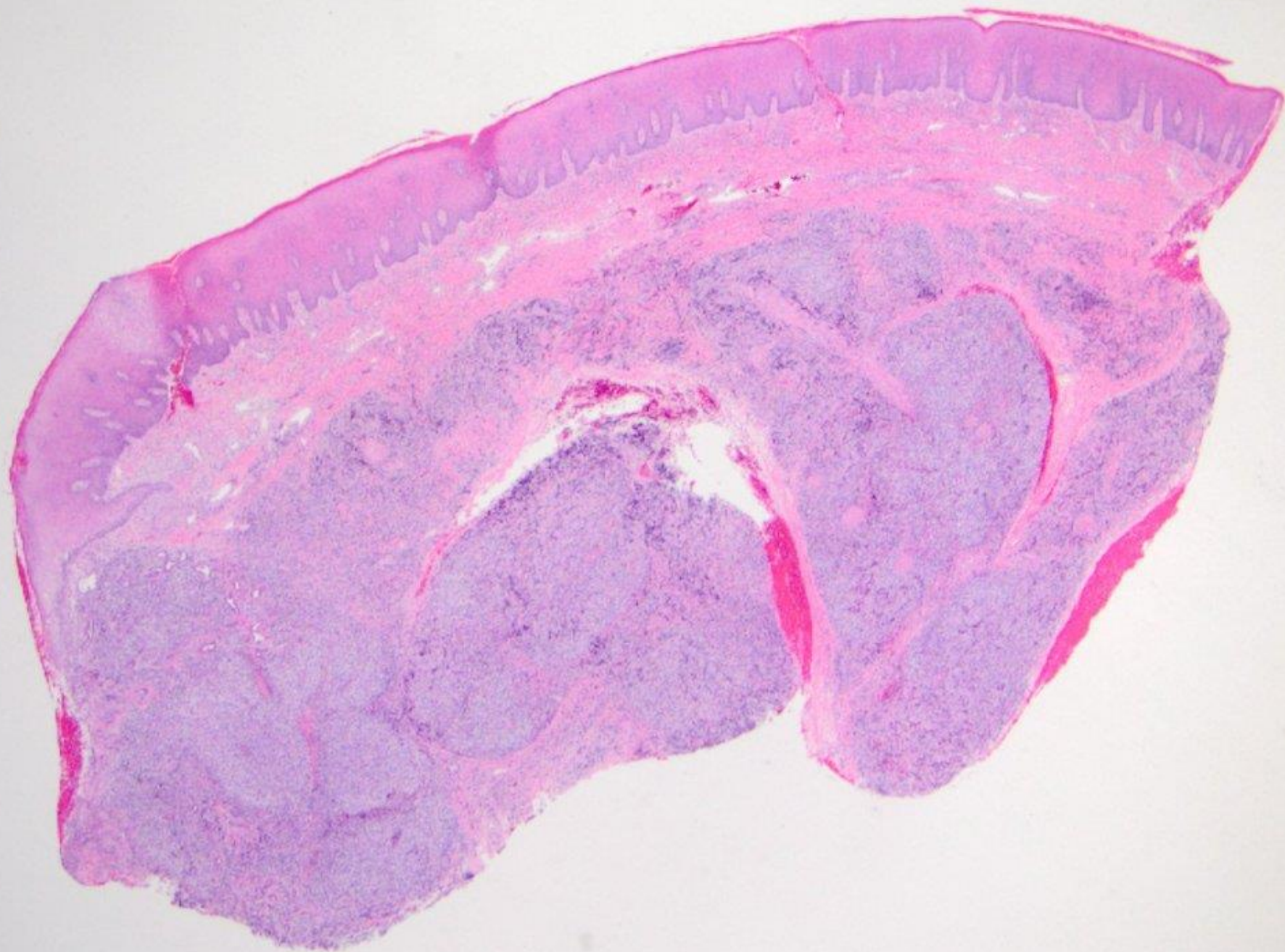
osteoporotic bone marrow defect

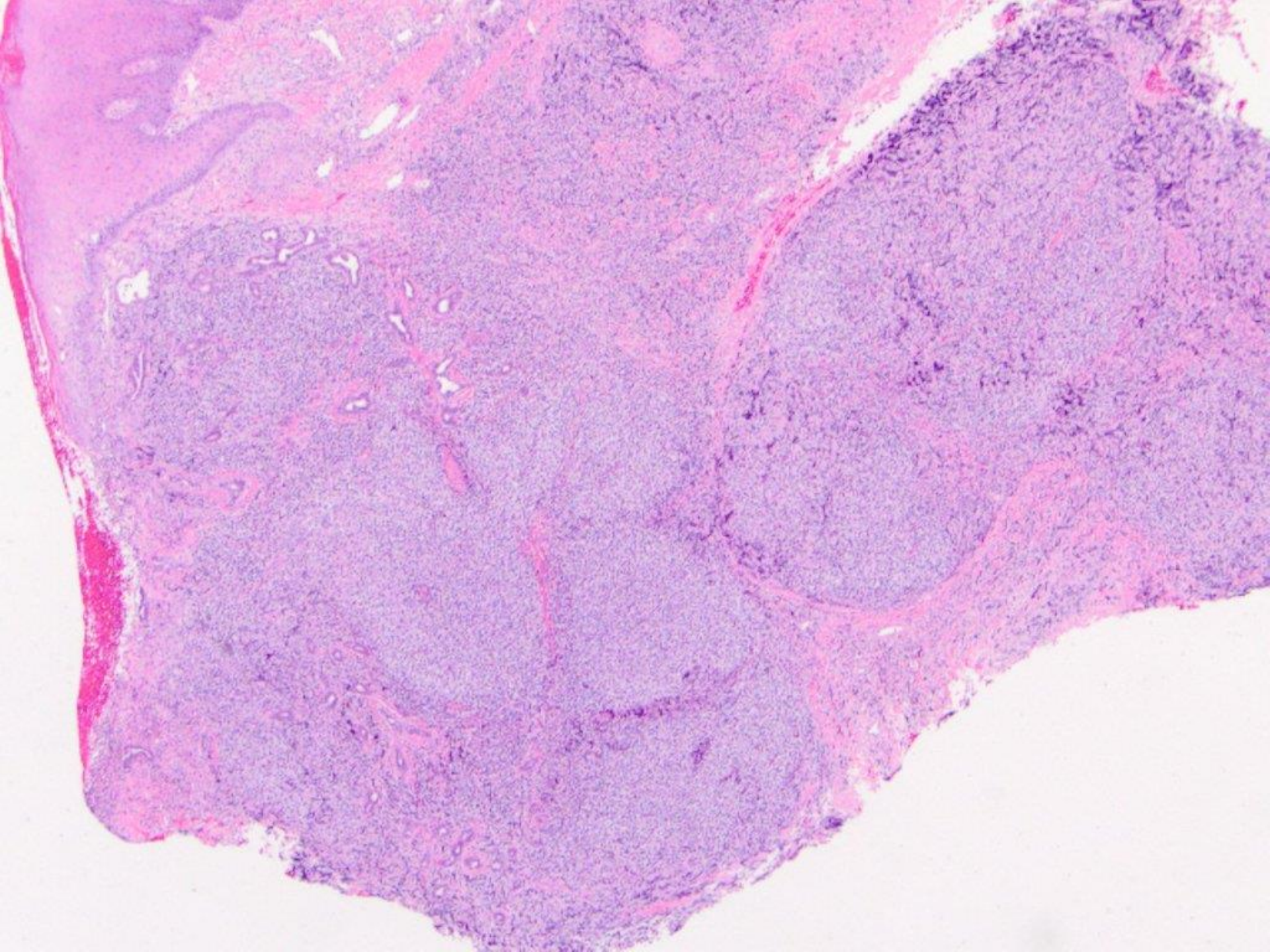


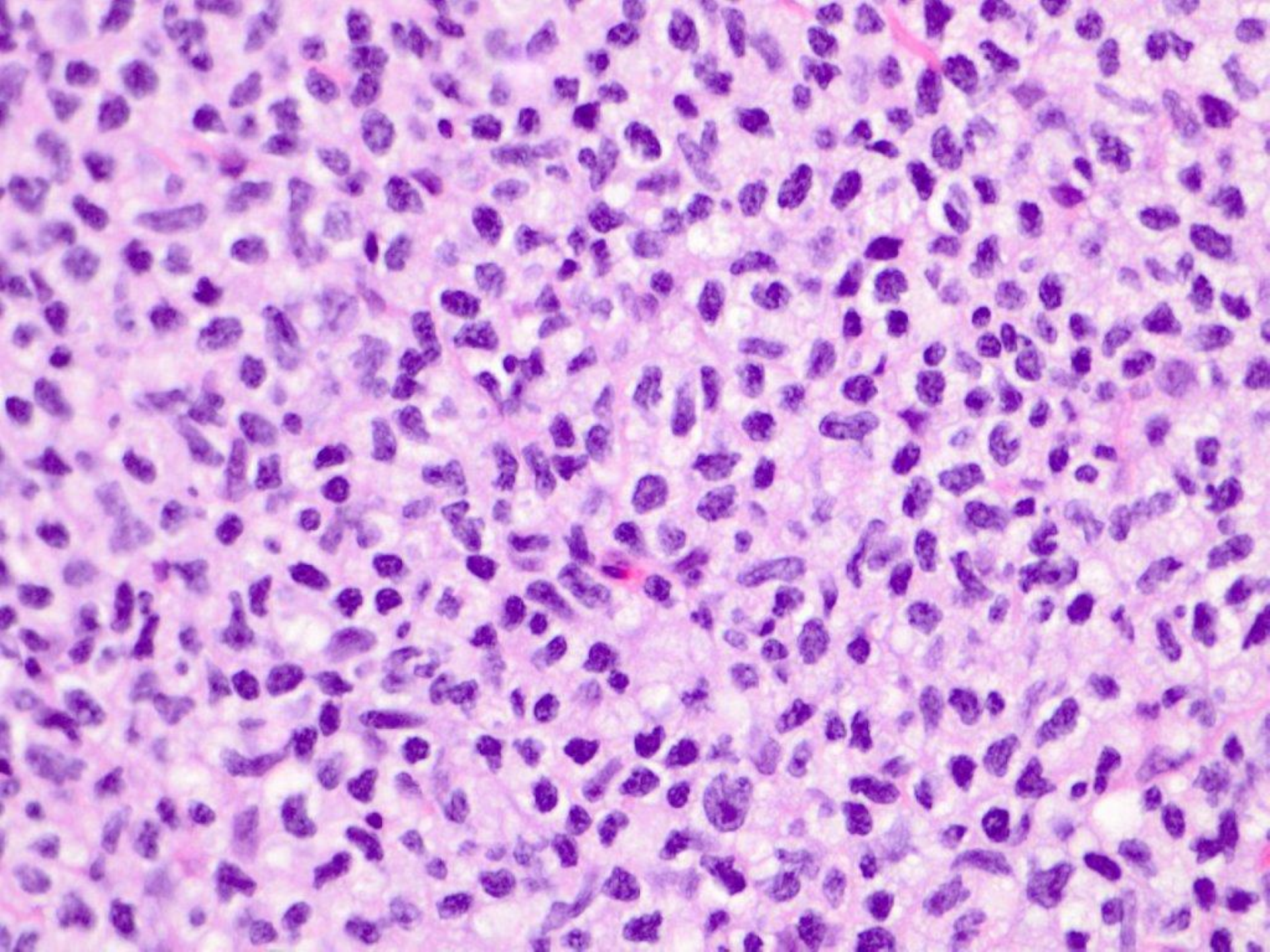


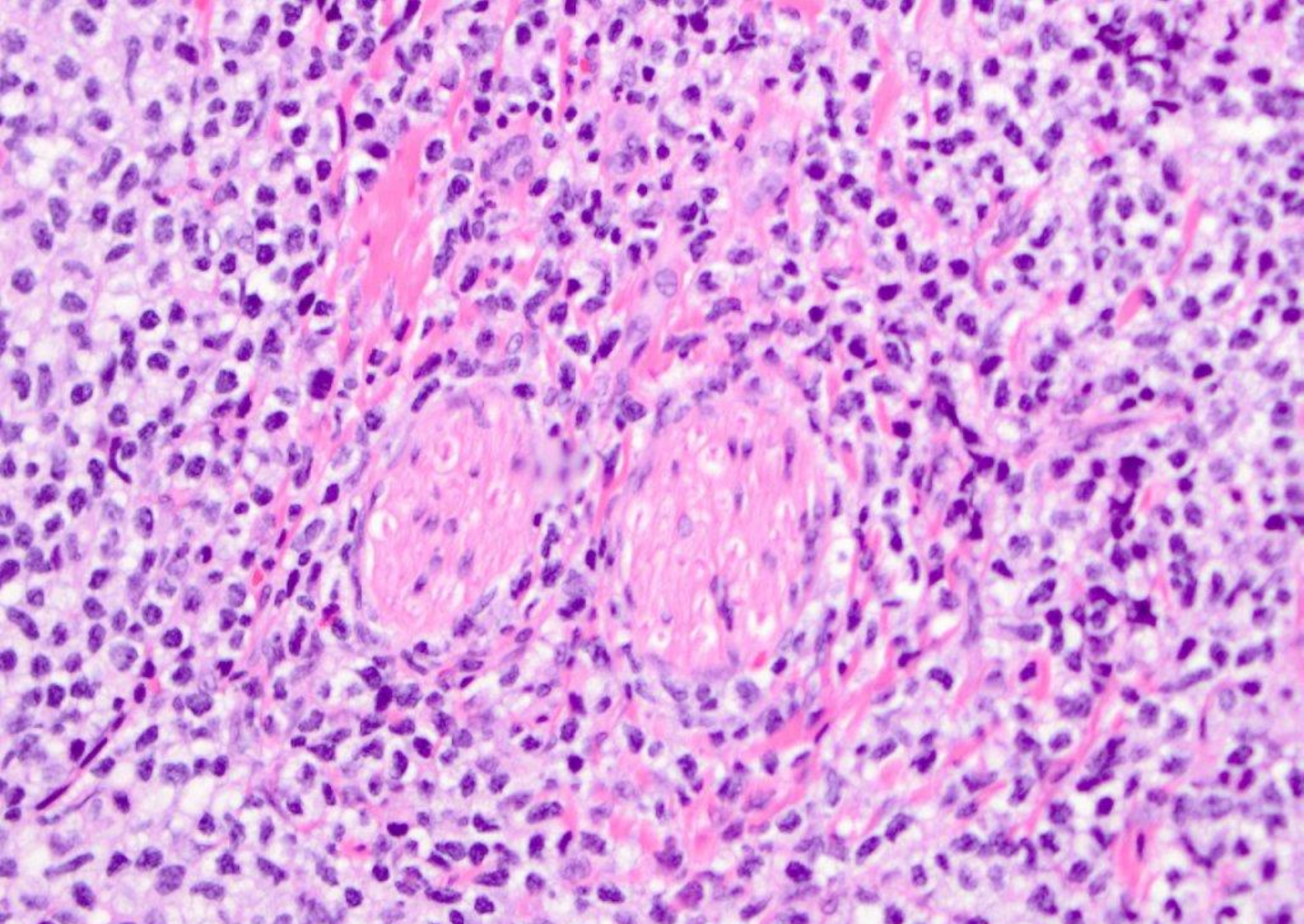


consistent with focal osseous dysplasia

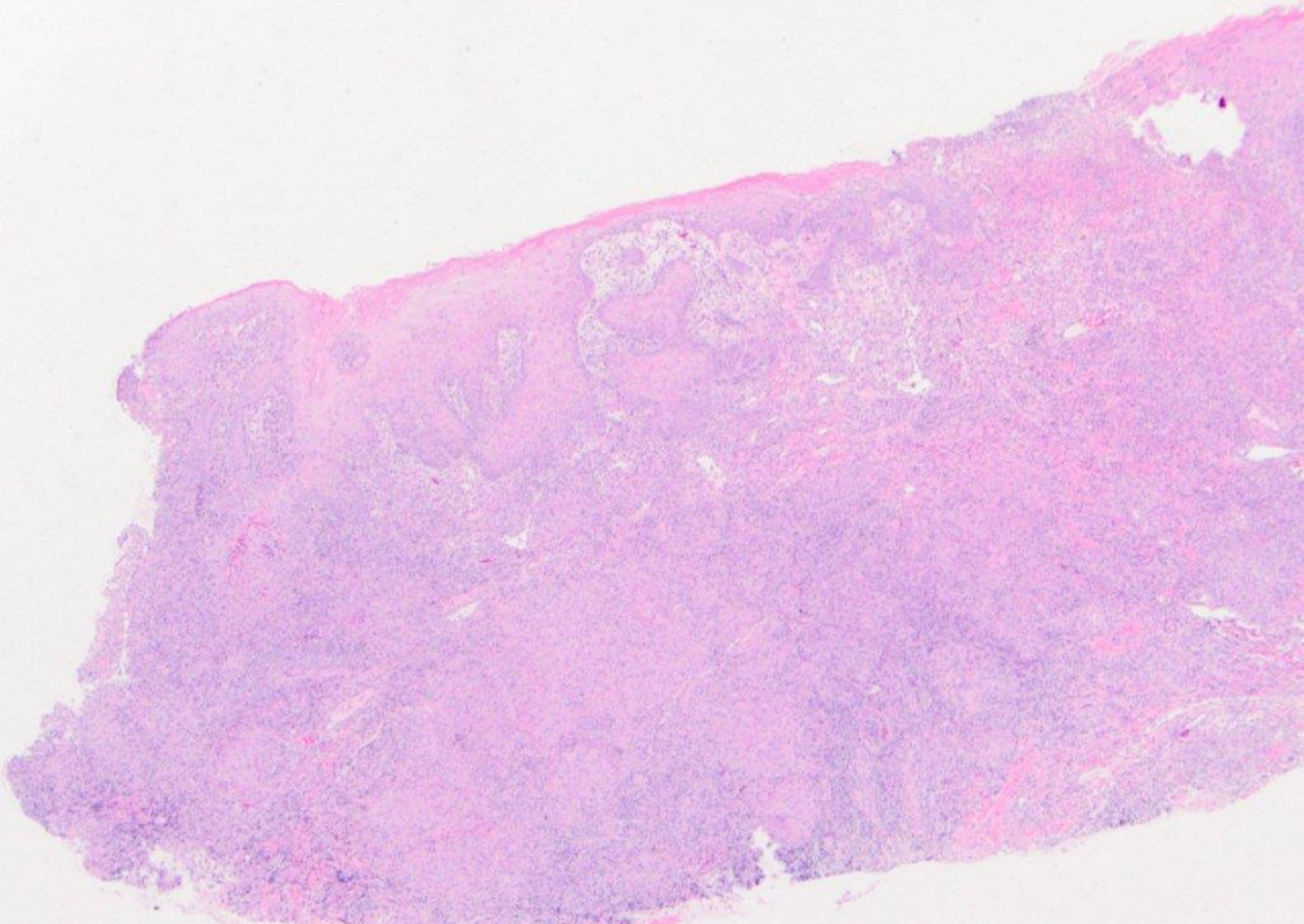




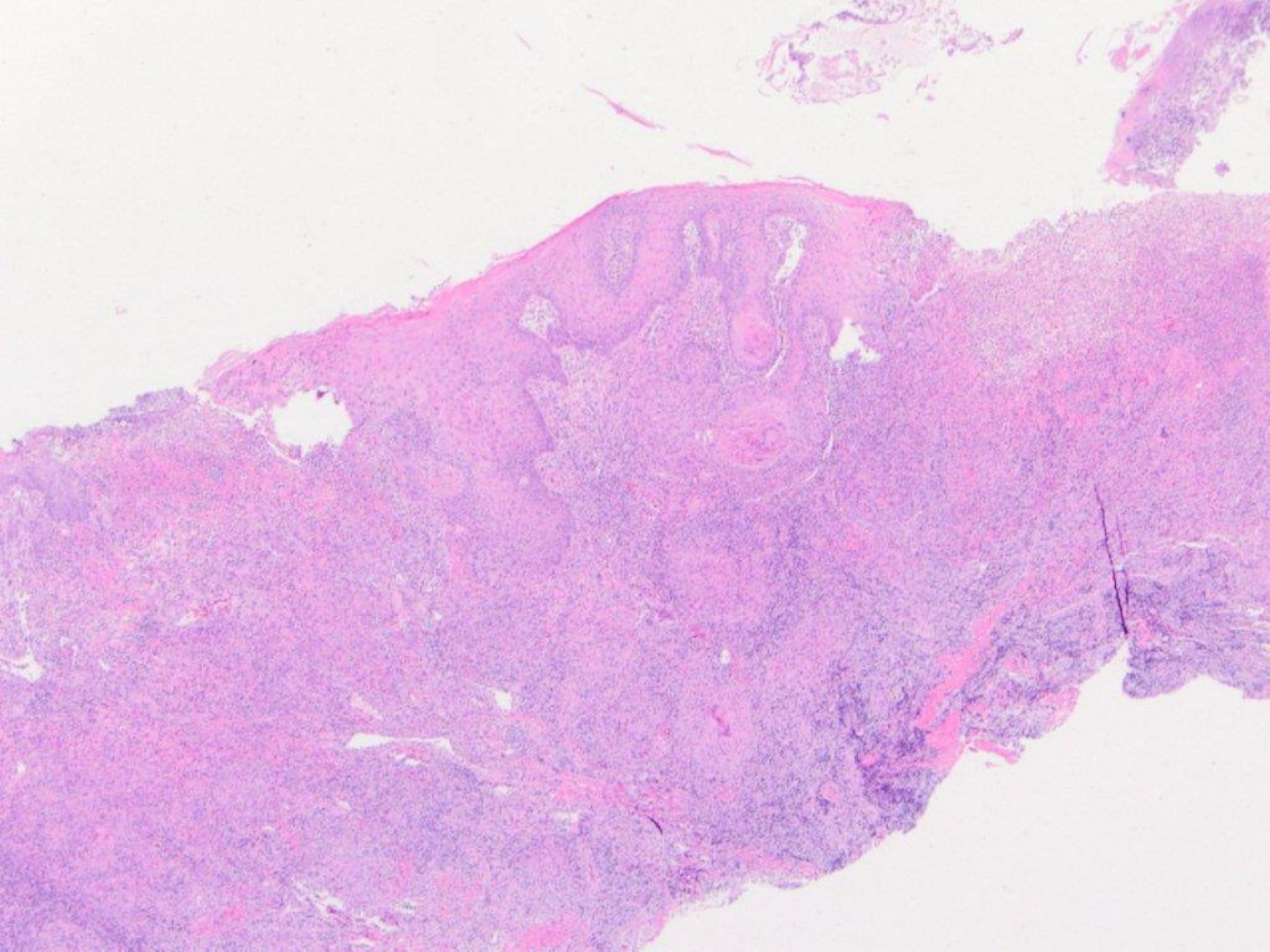


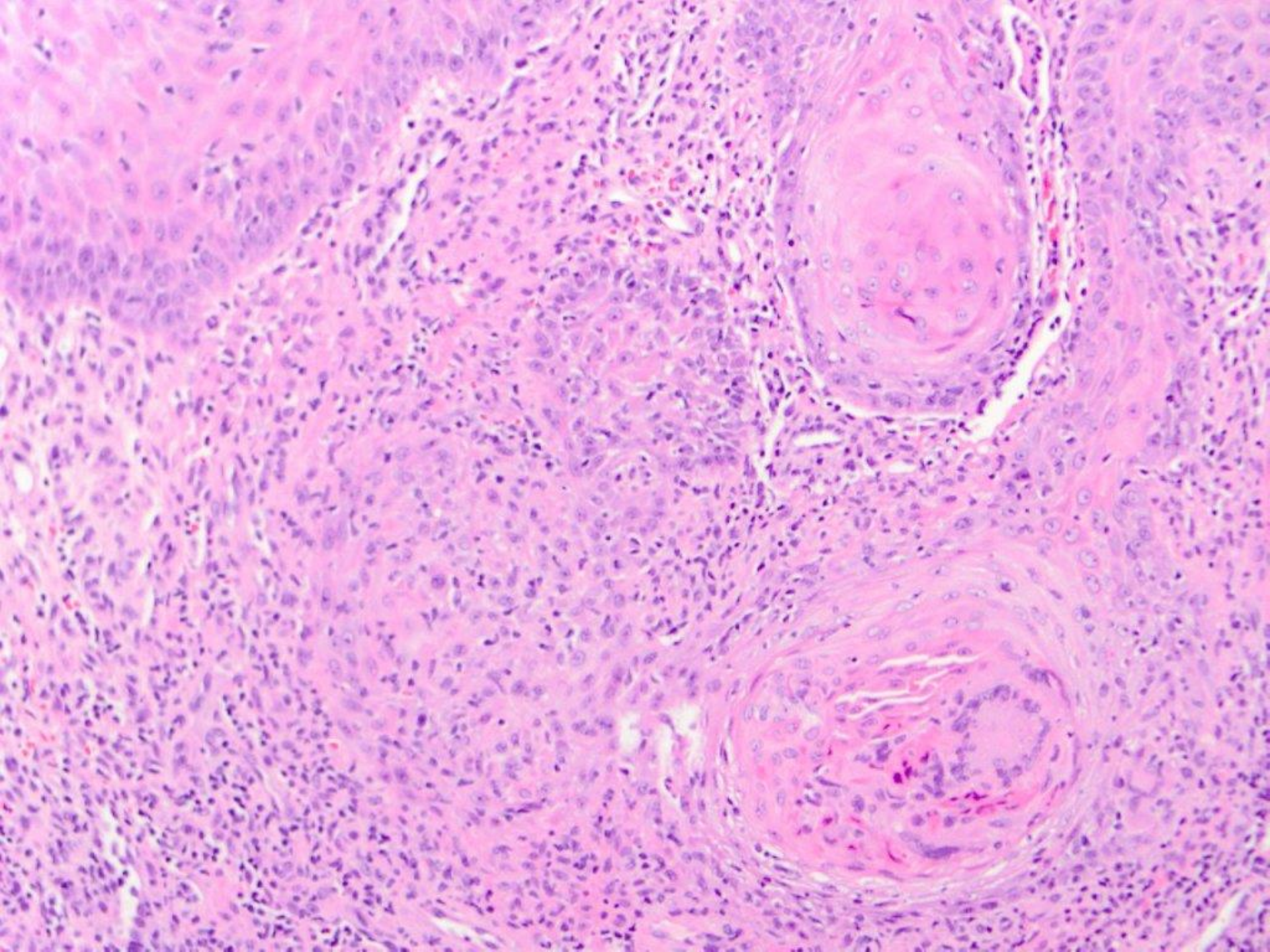


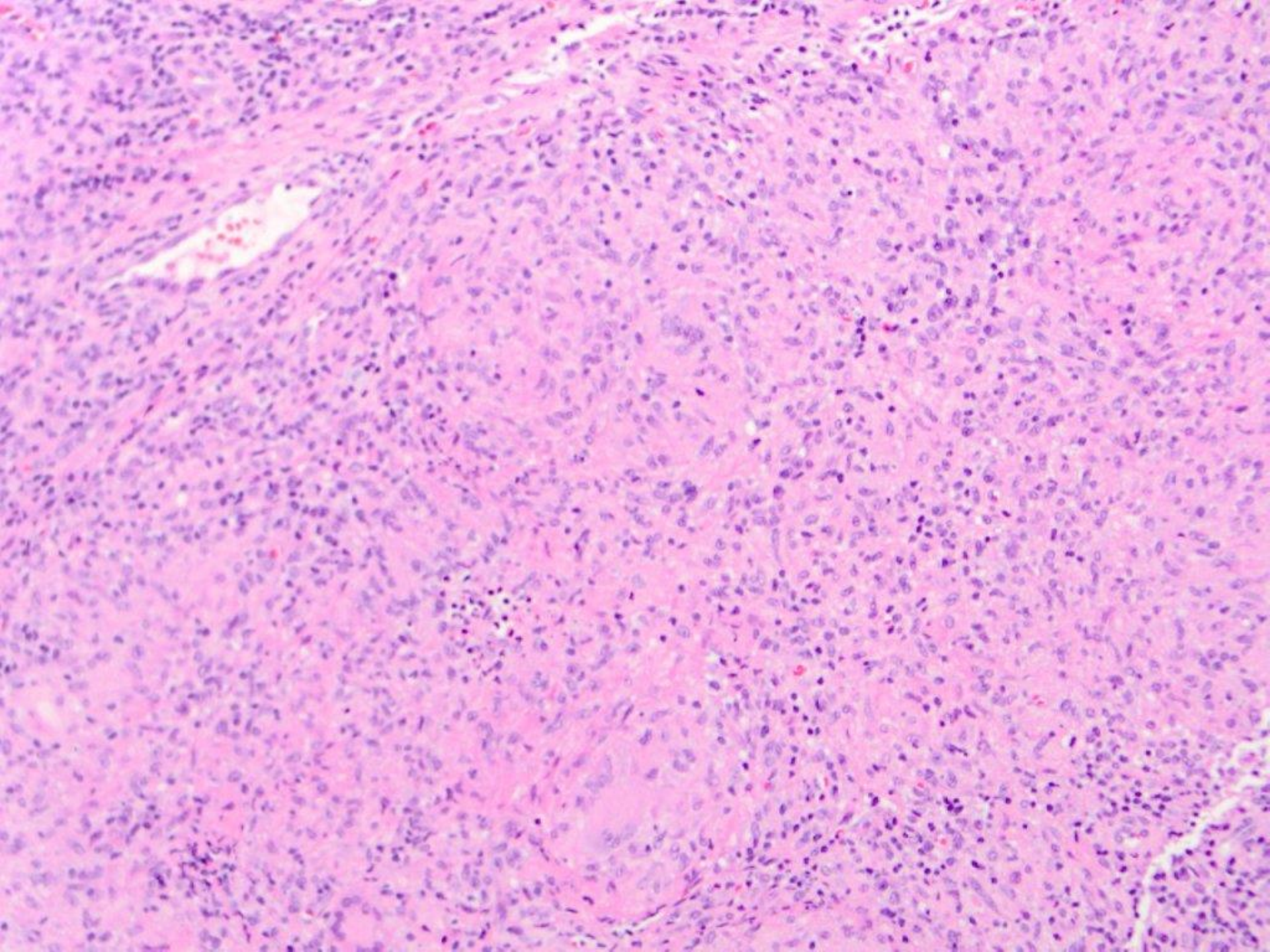
follicular lymphoma

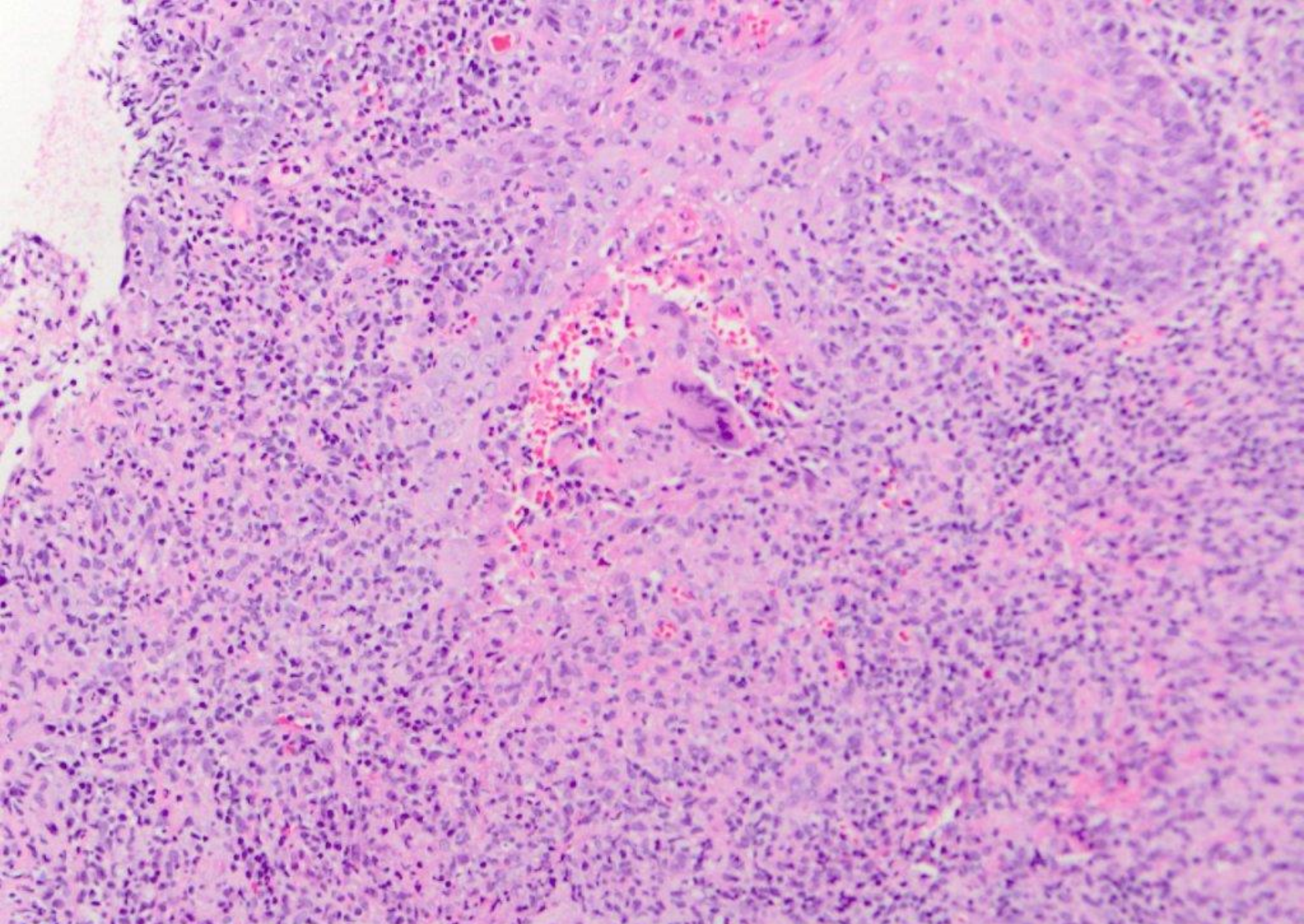


generalized edema and erythema, gingival tissues

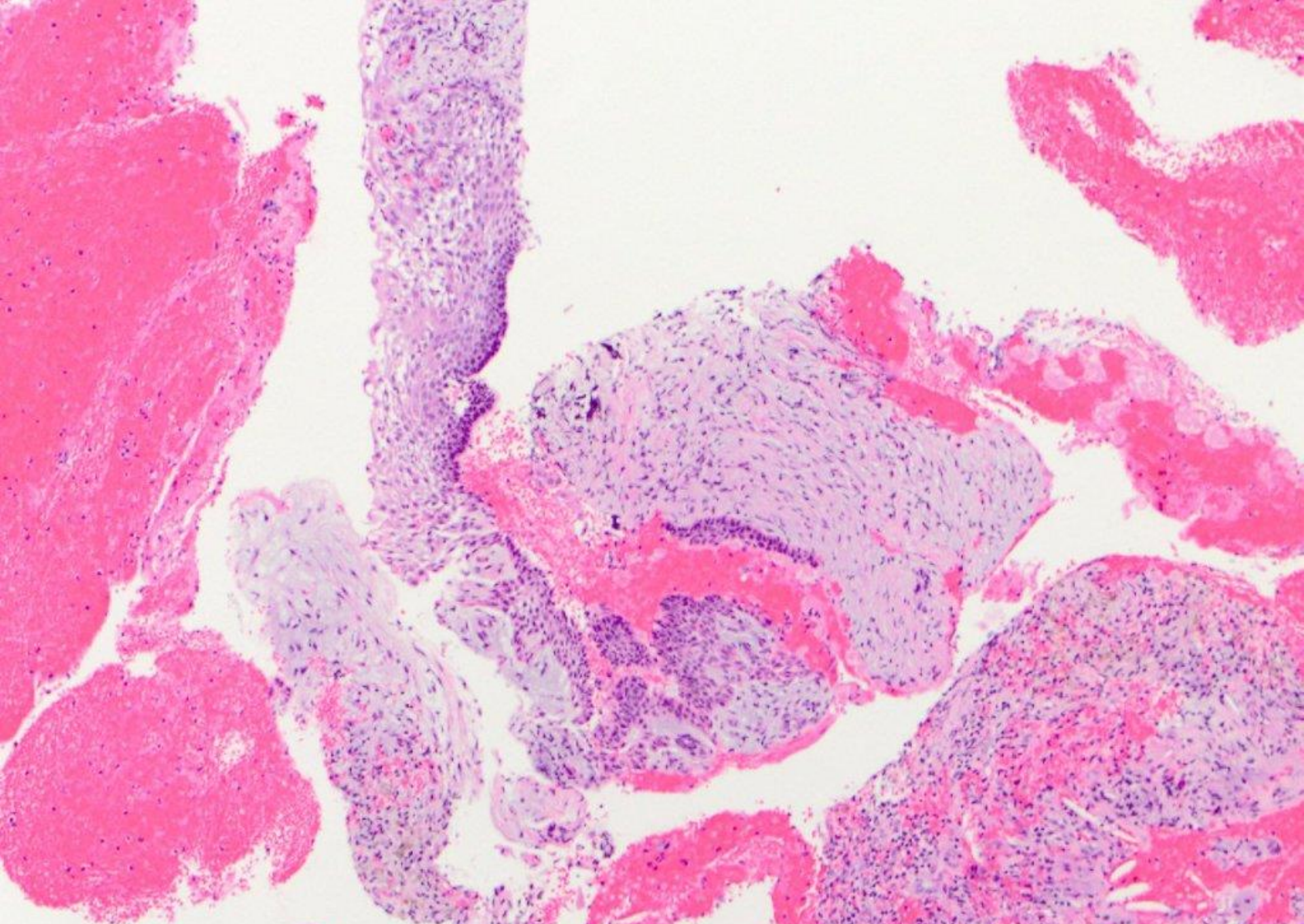




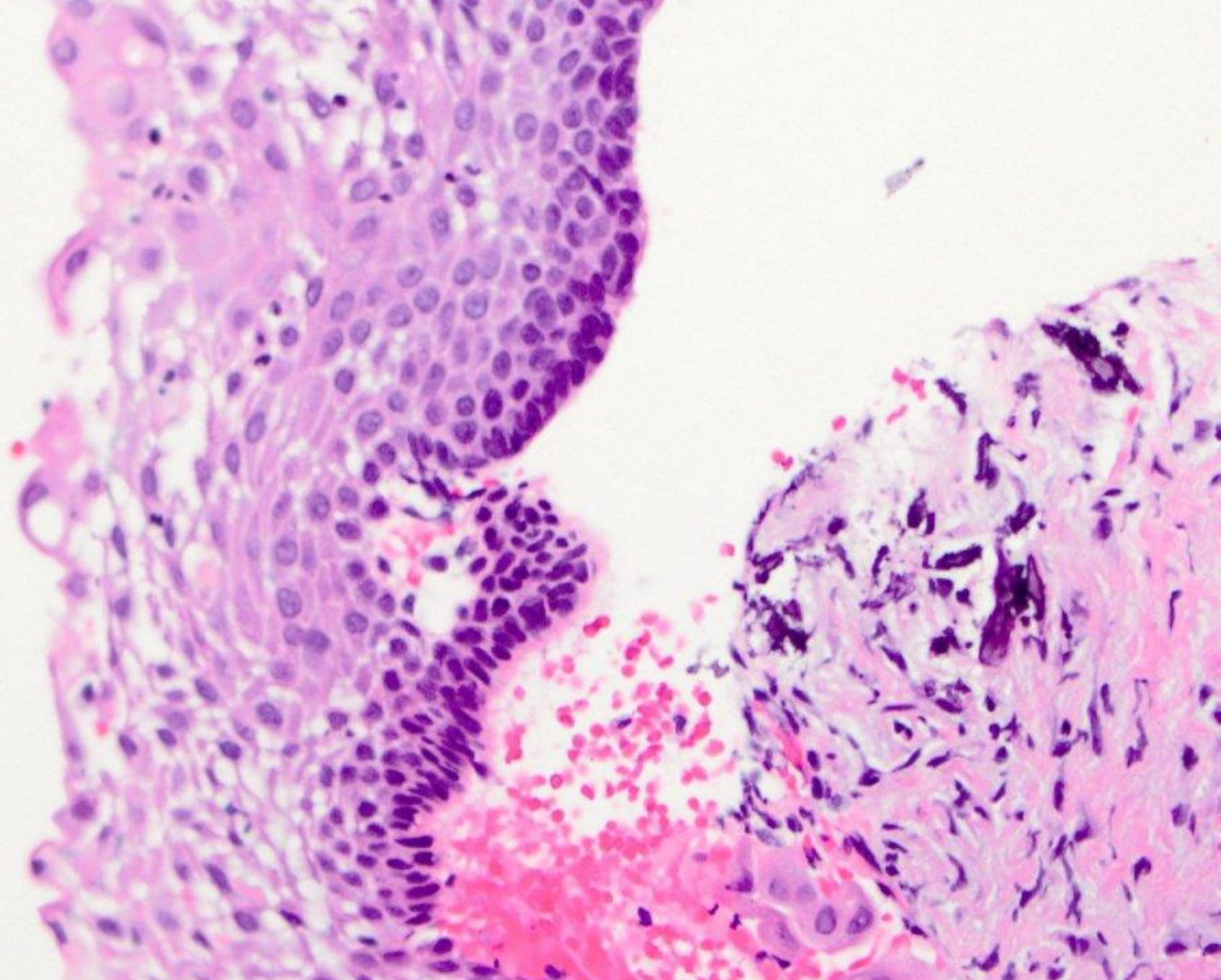




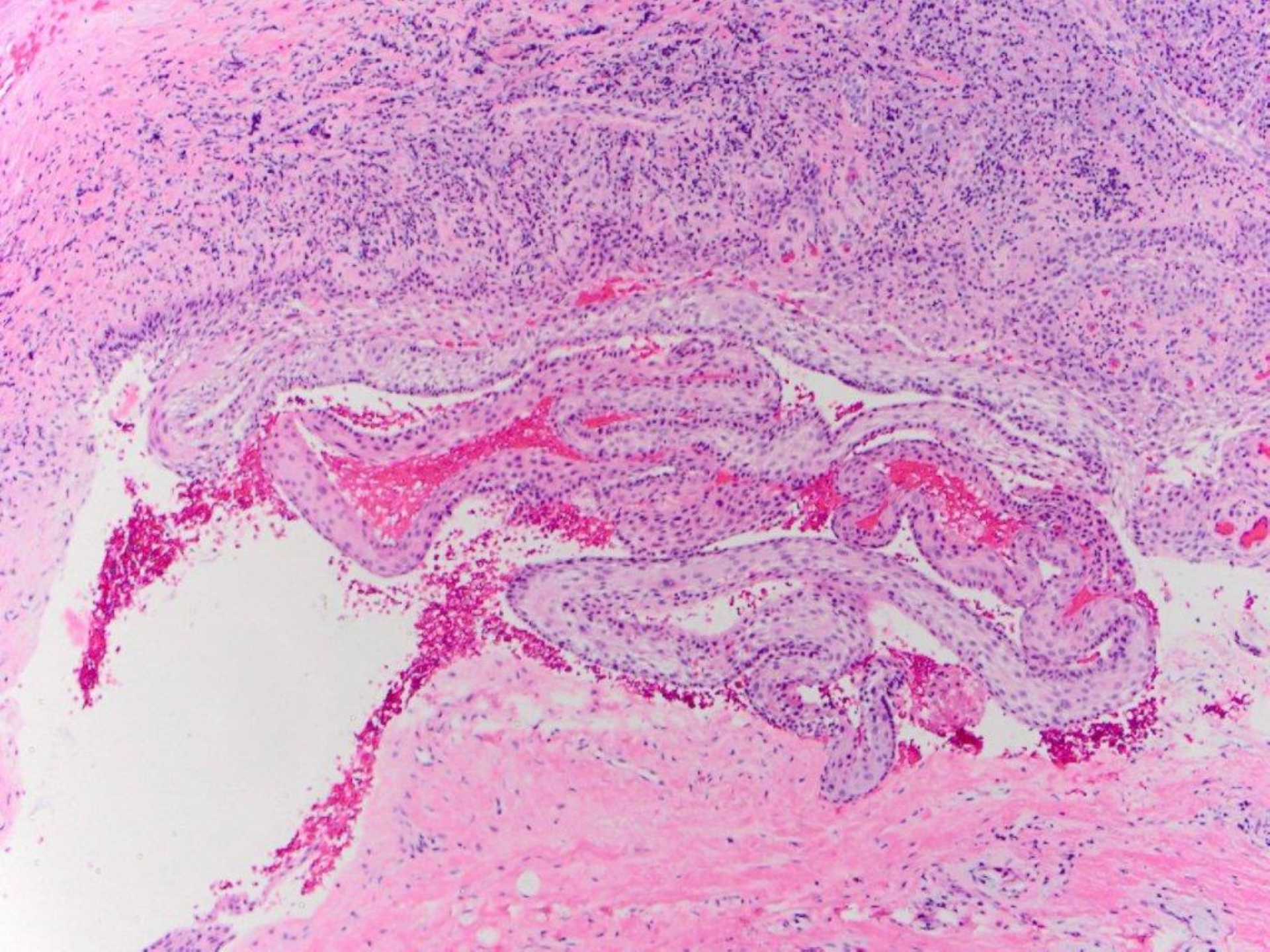
granulomatous inflammation

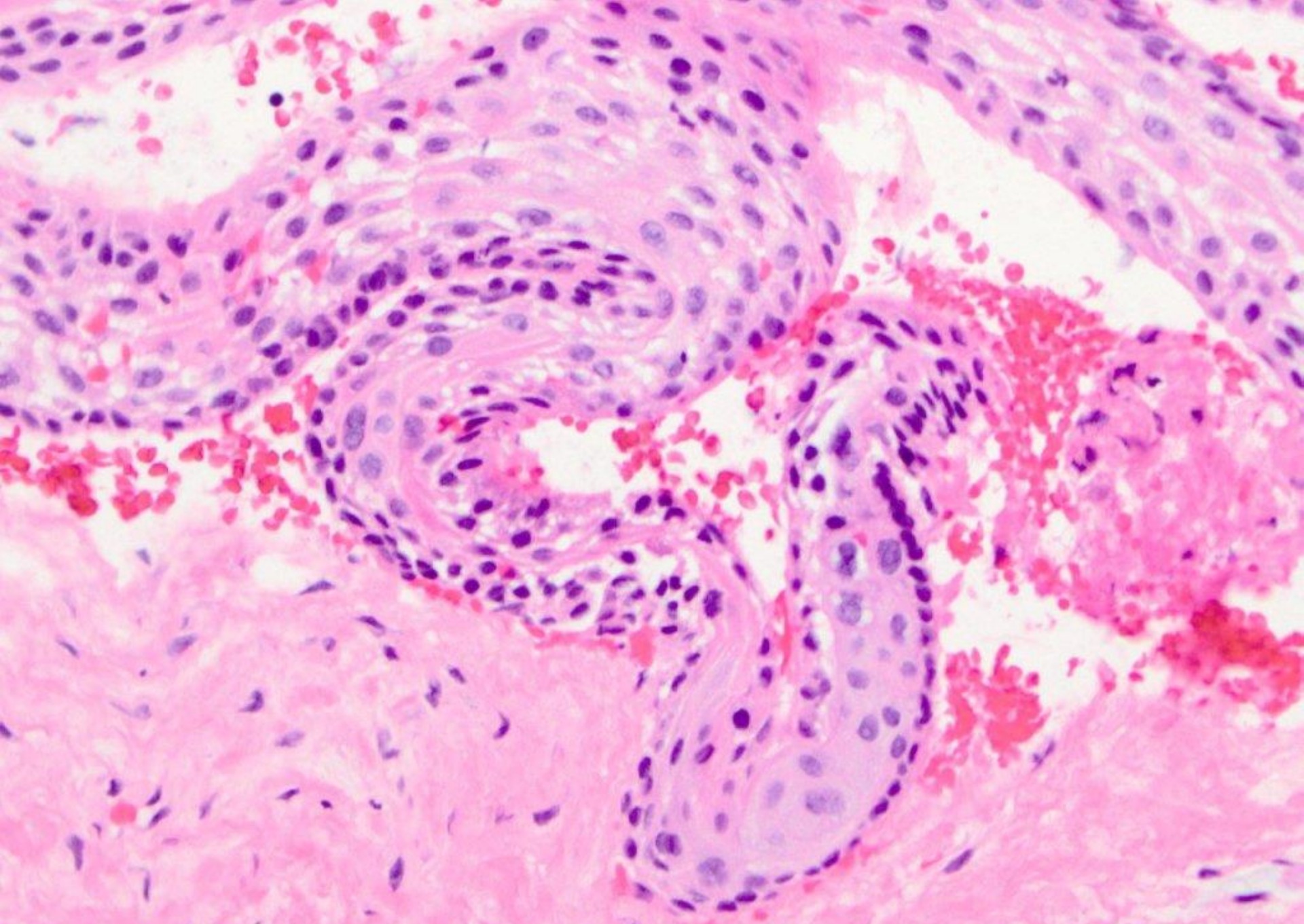


multilocular radiolucency left body and angle of mandible

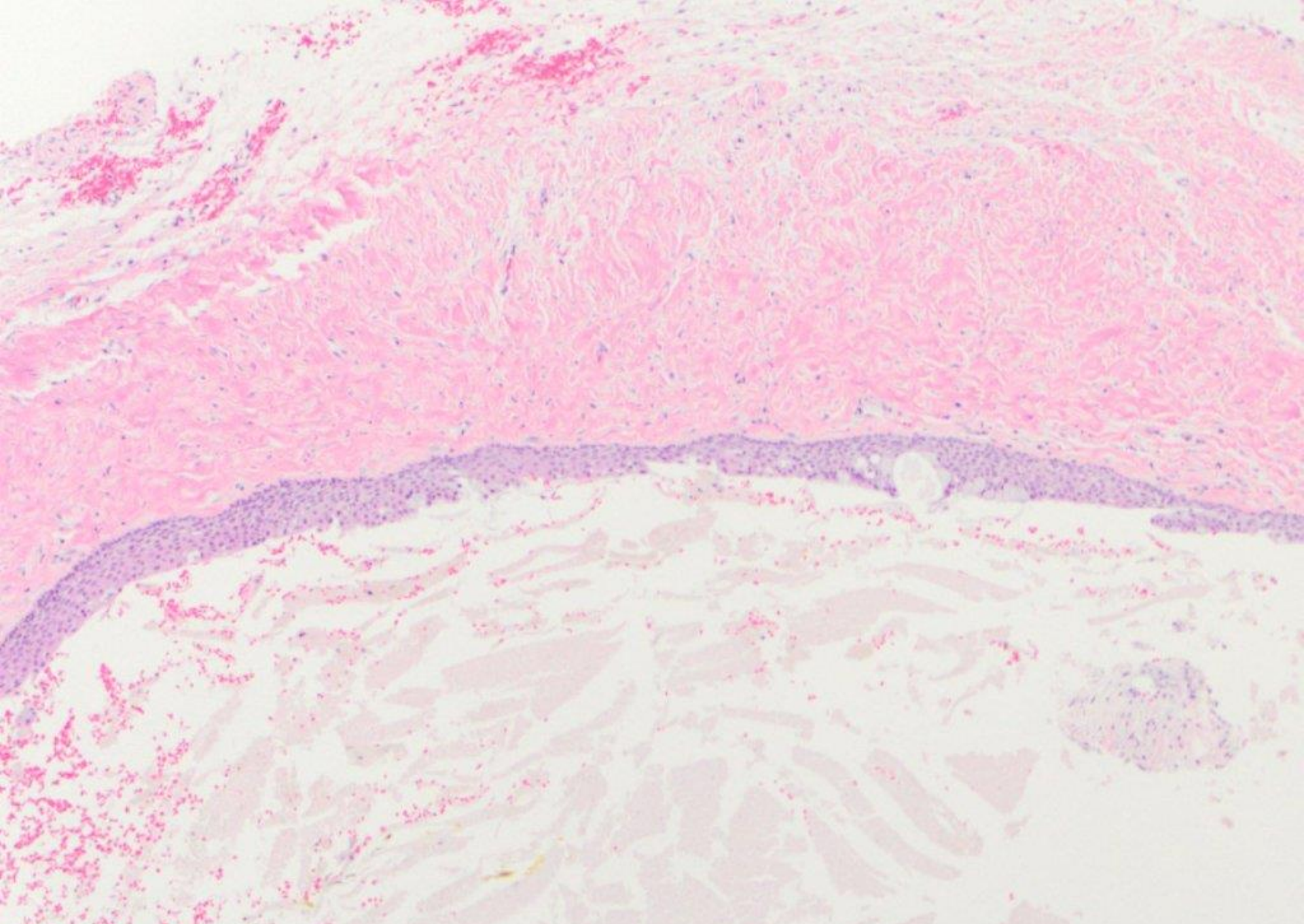


suggestive of ameloblastoma

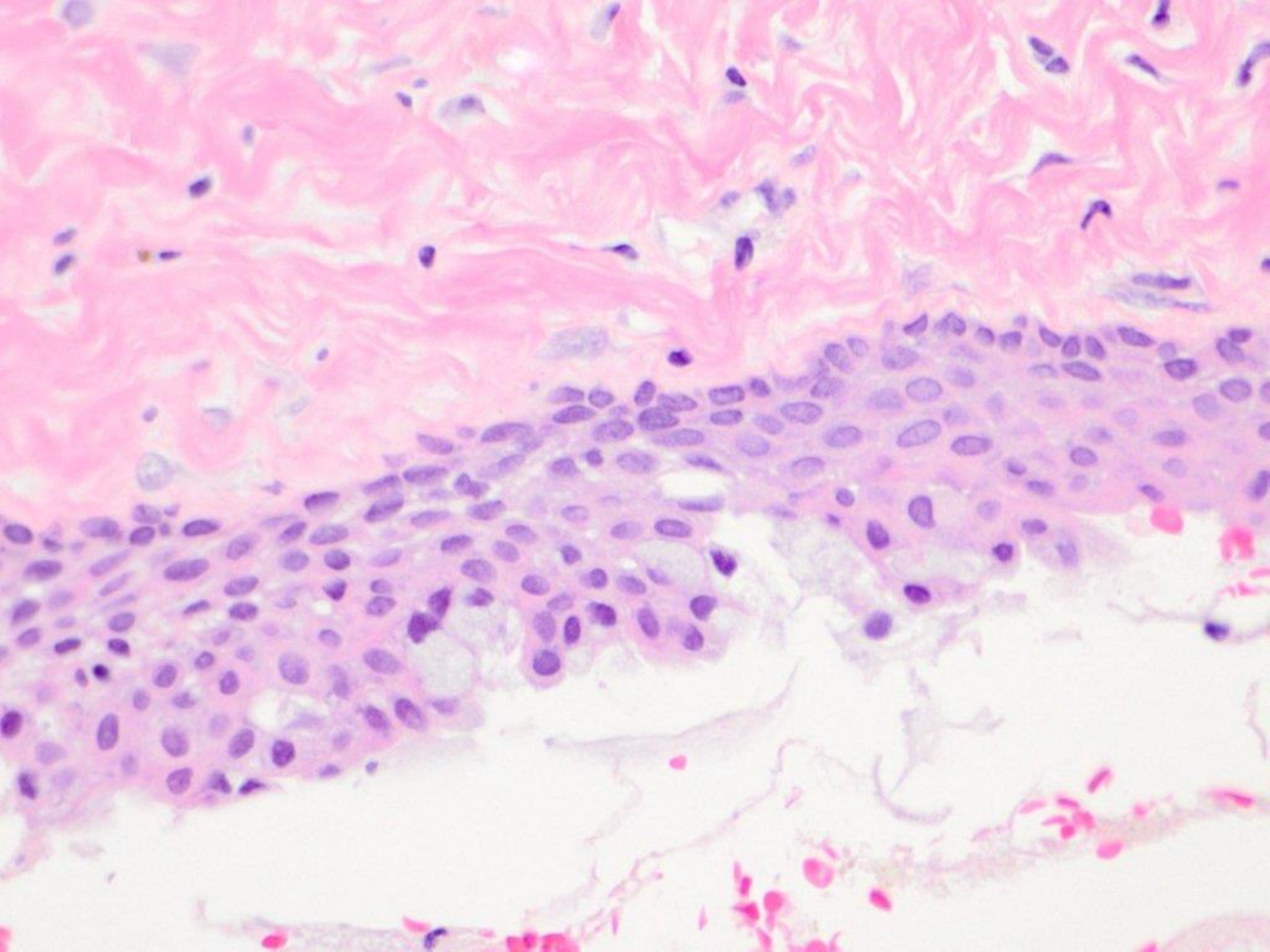


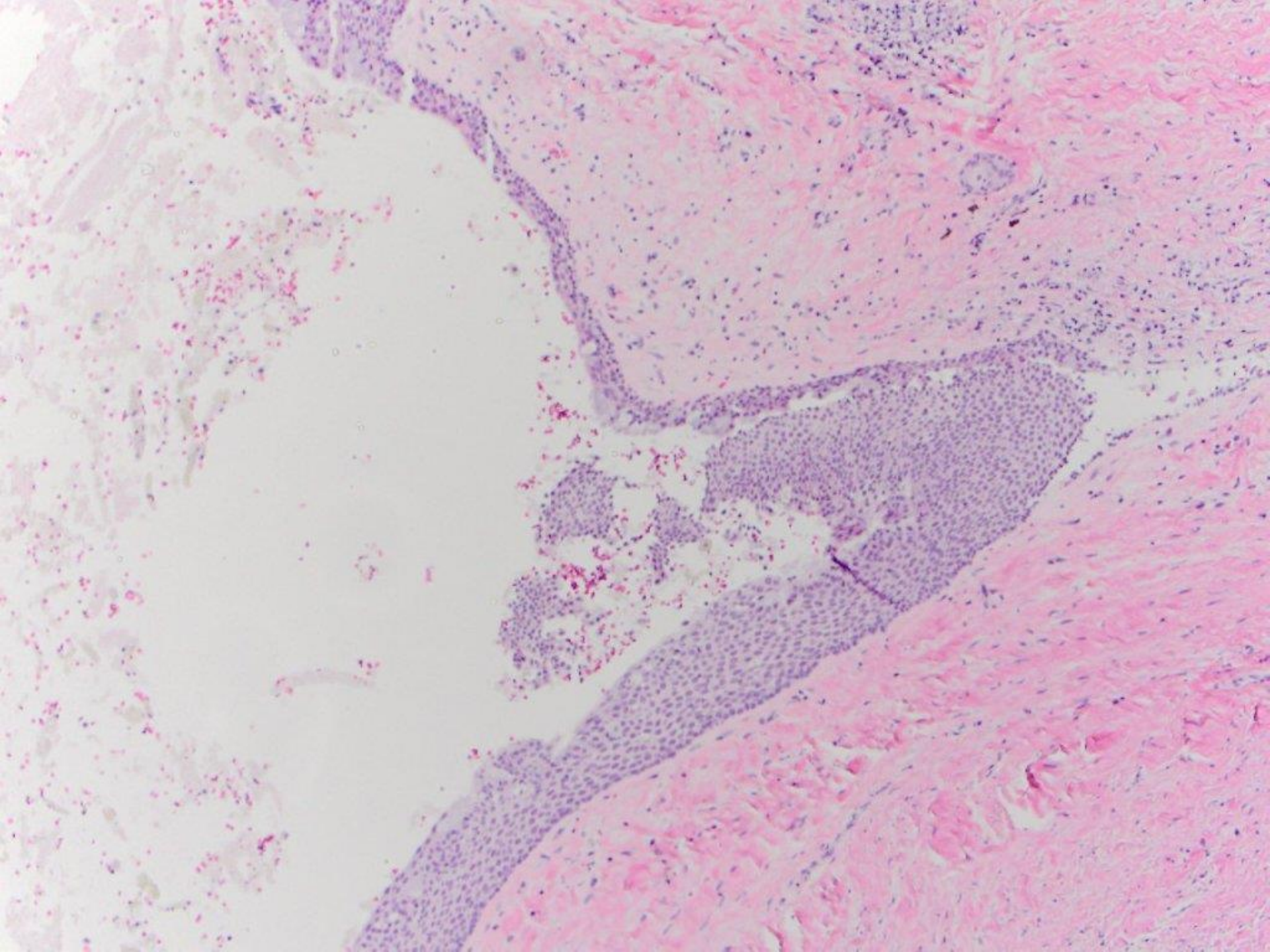


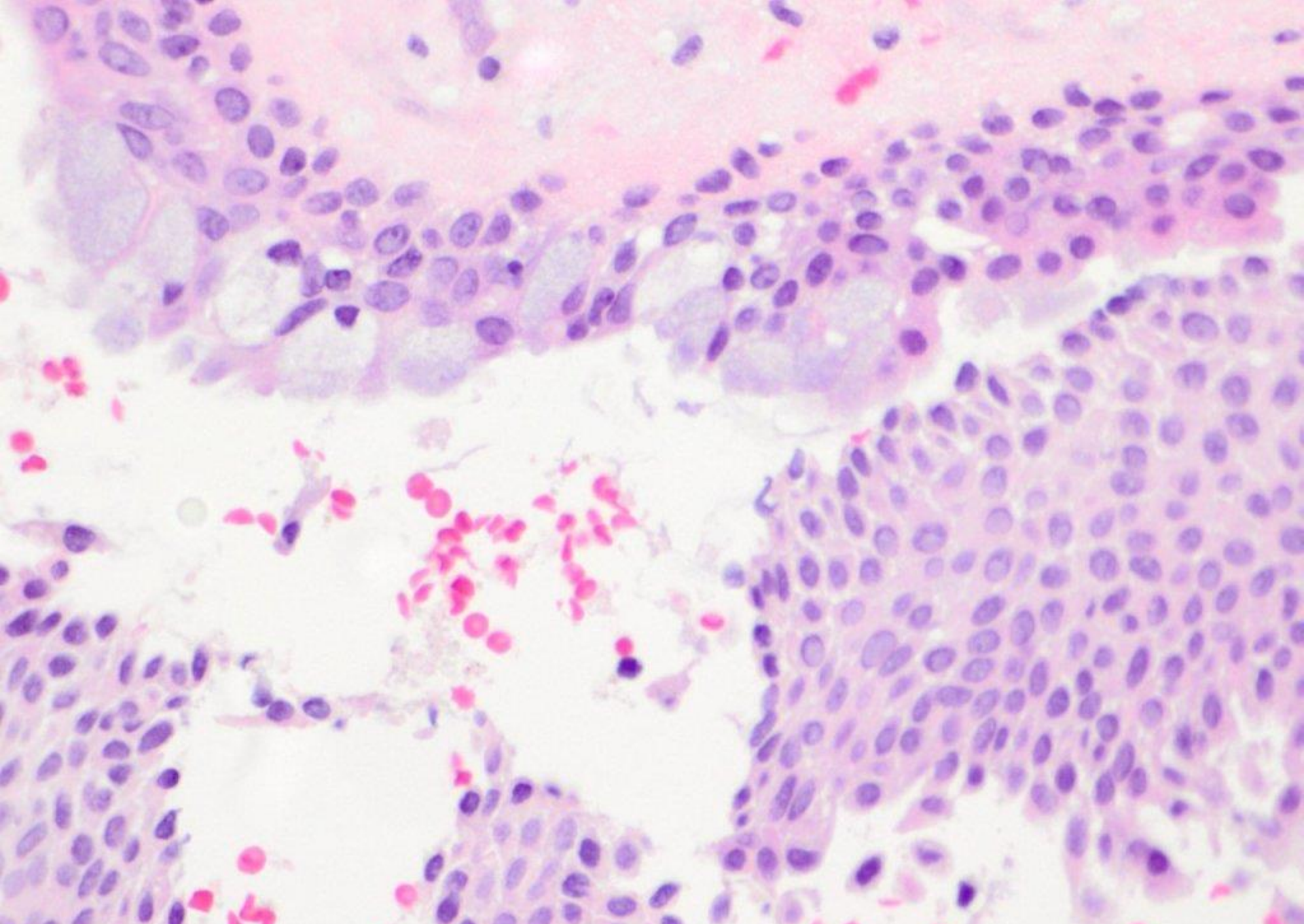
odontogenic keratocyst (keratocystic odontogenic tumor)



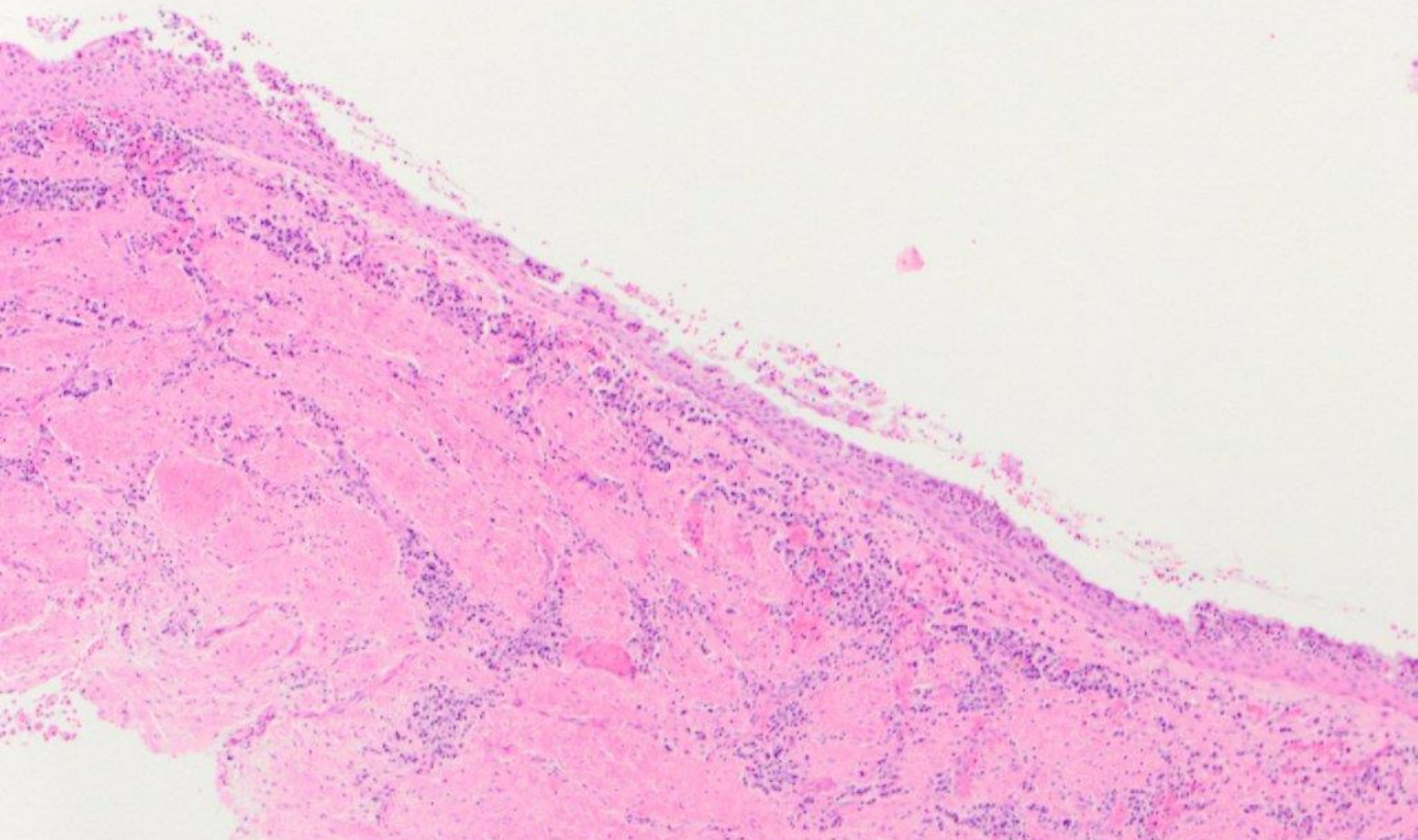
radiolucency, posterior mandible



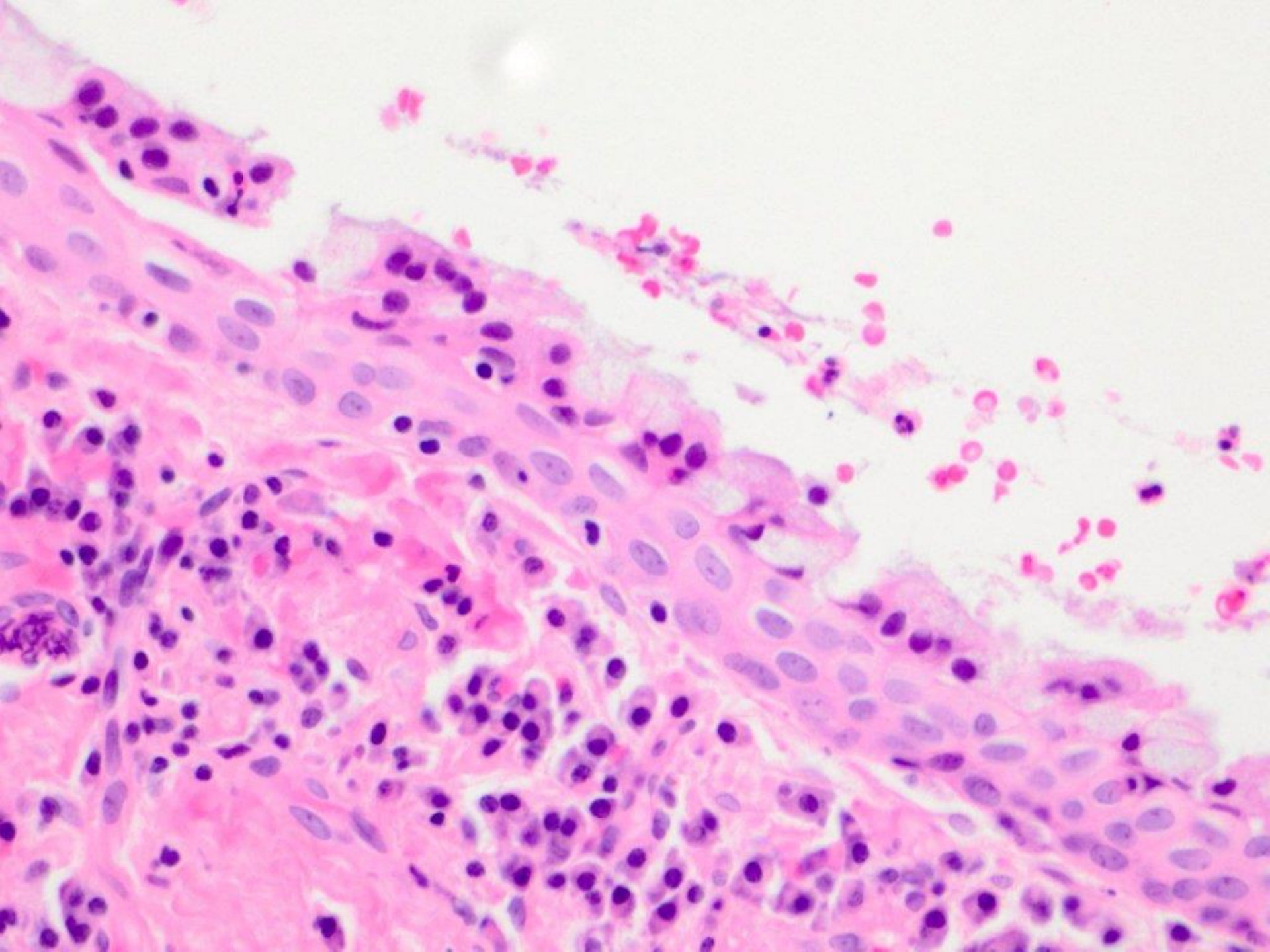


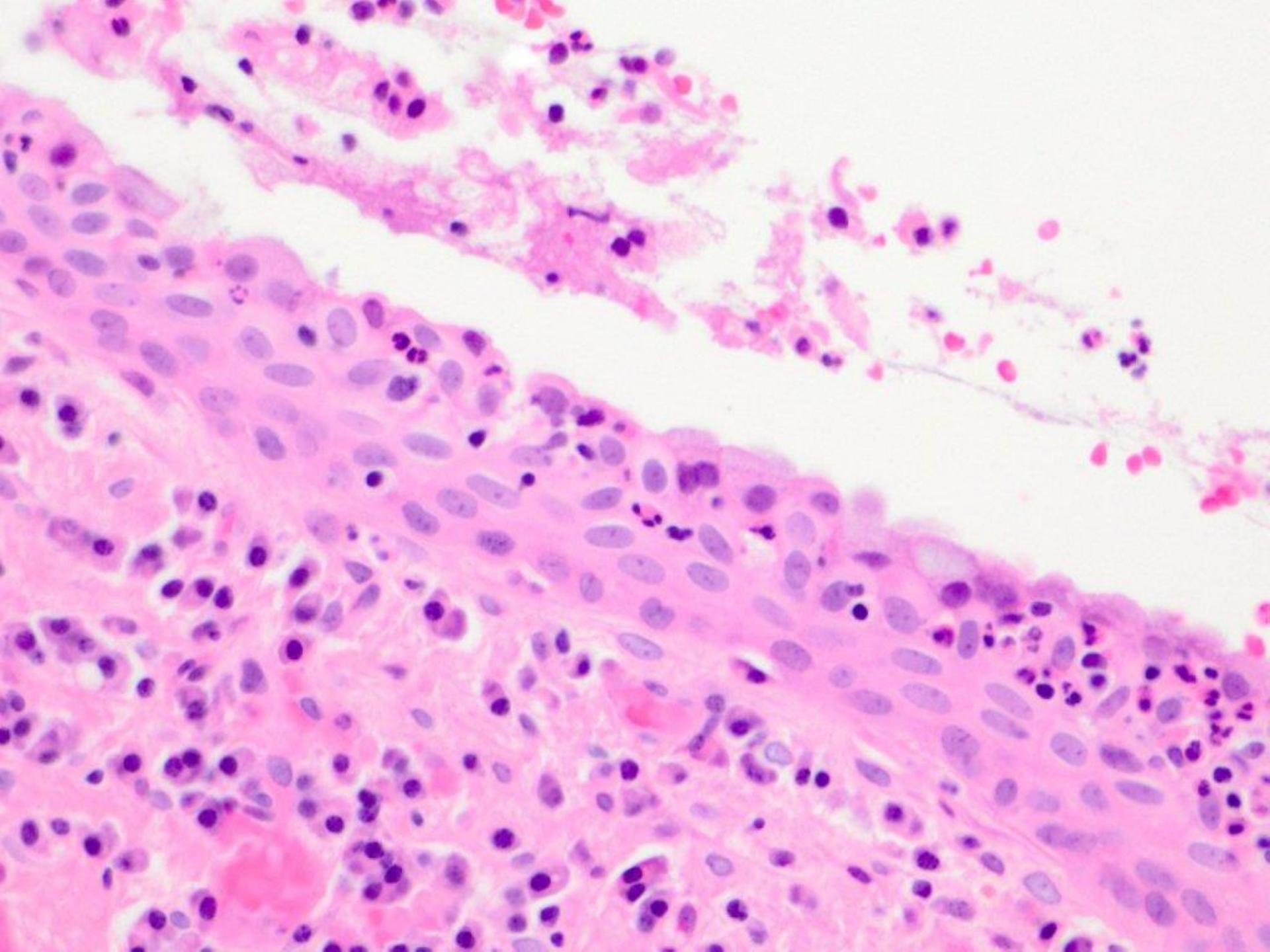


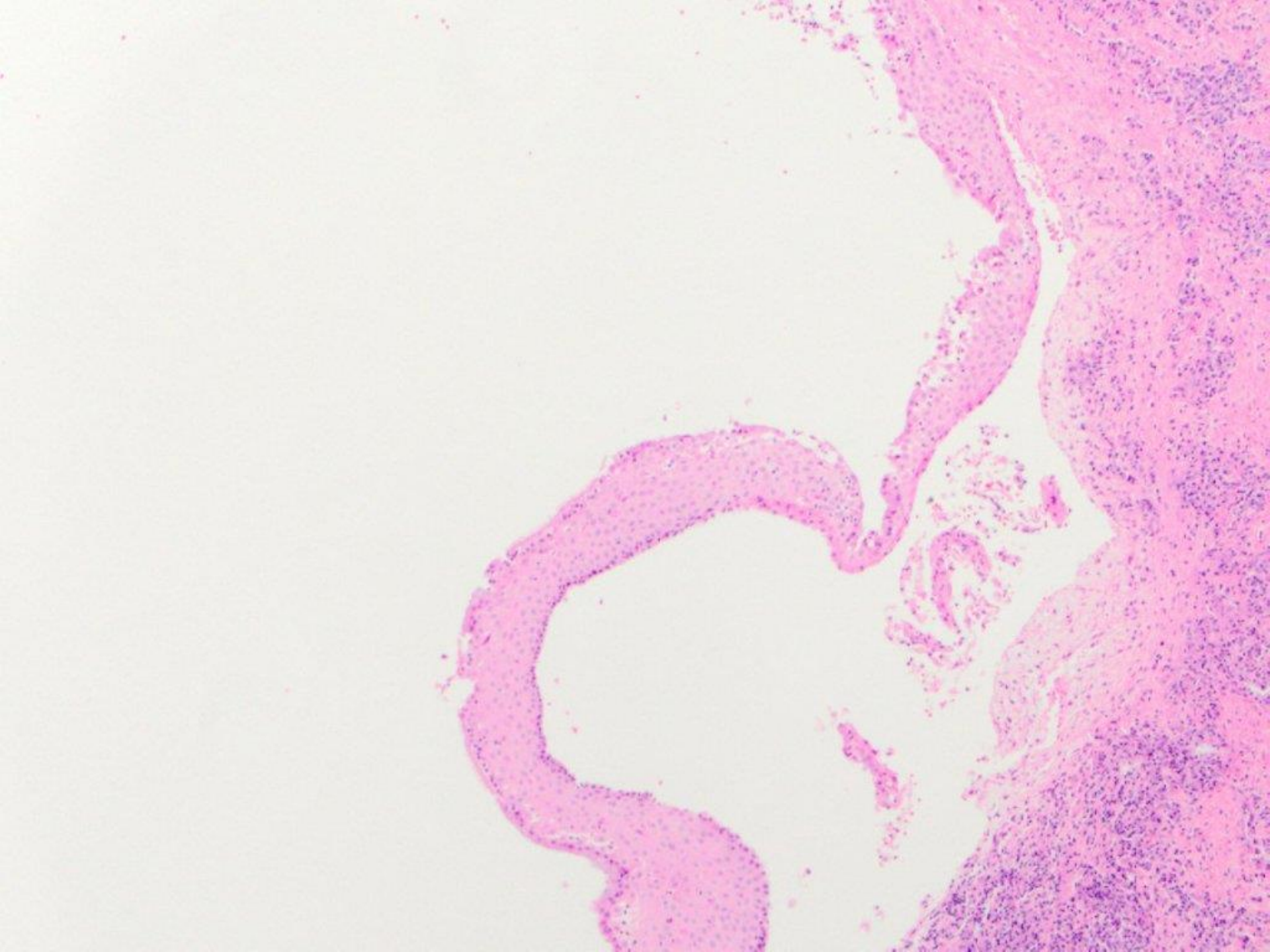
glandular odontogenic cyst

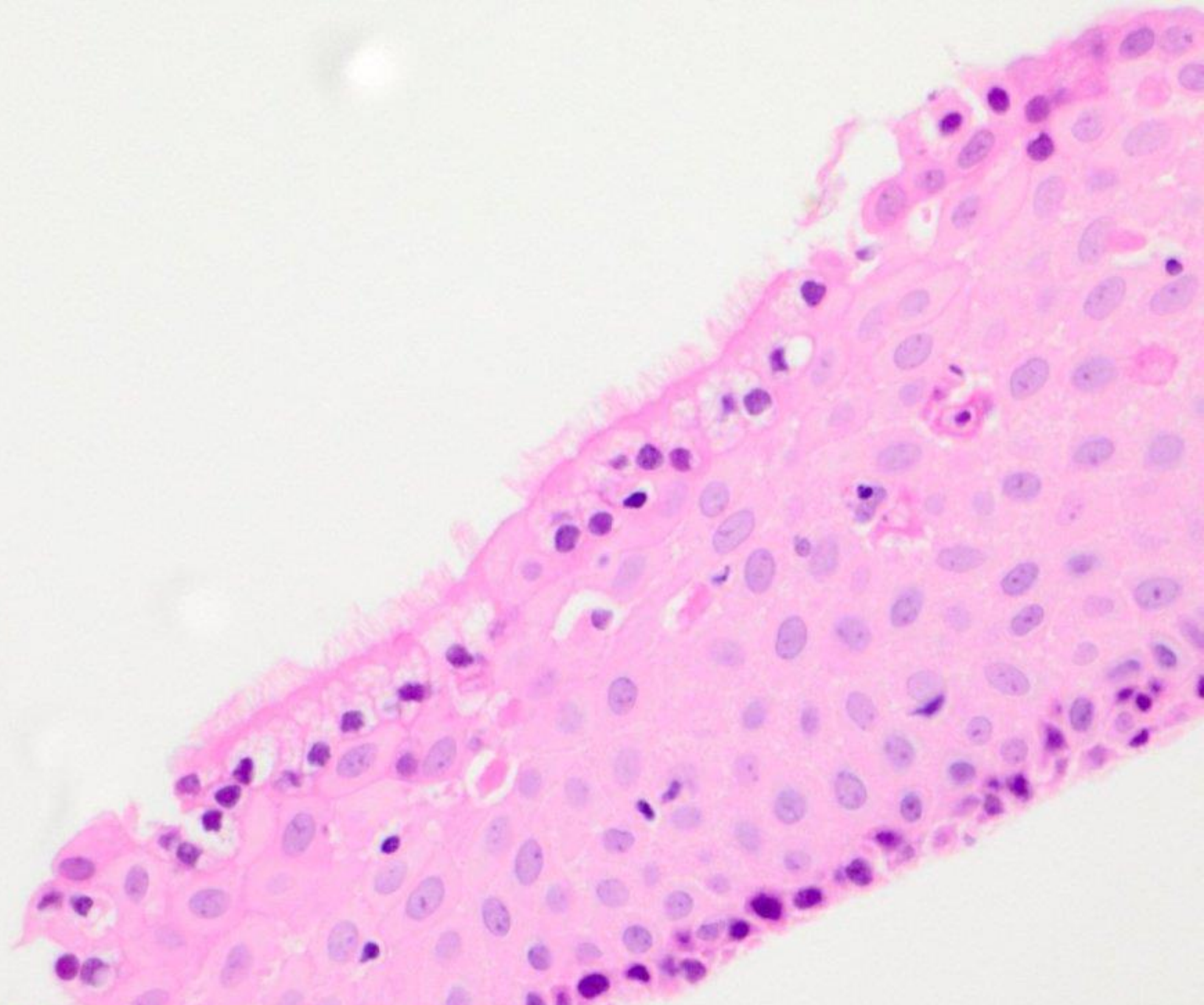


radiolucency, posterior mandible

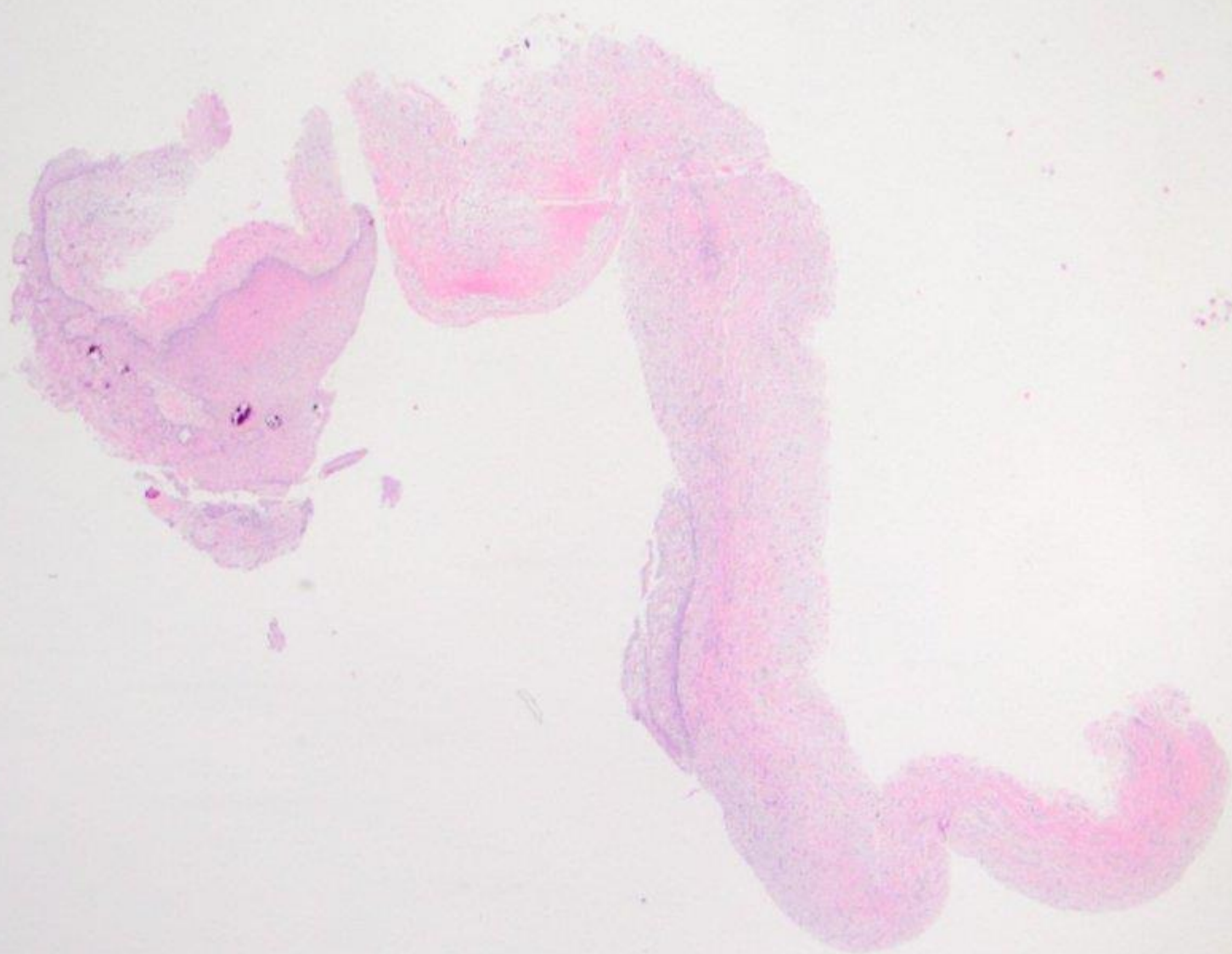



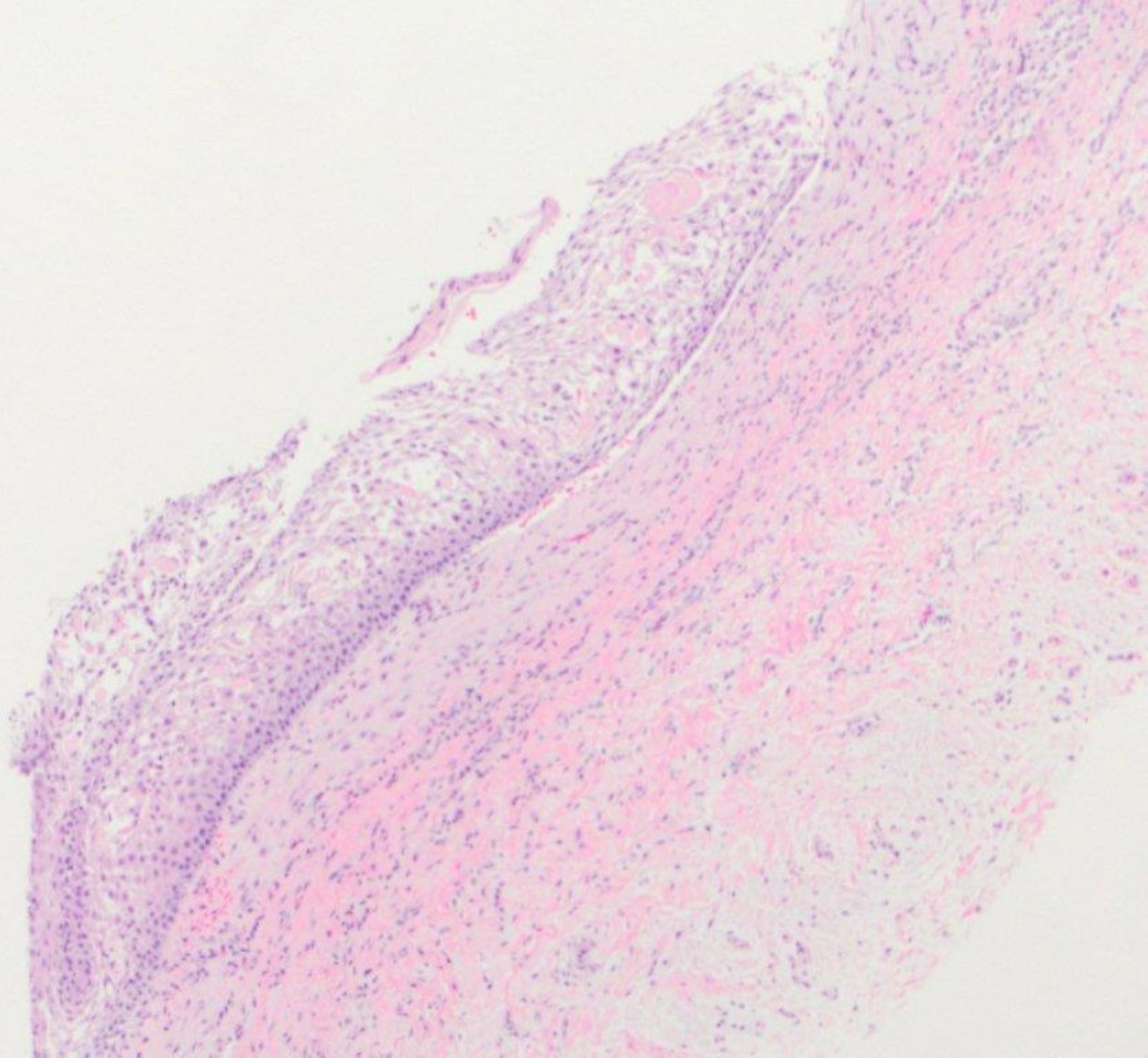


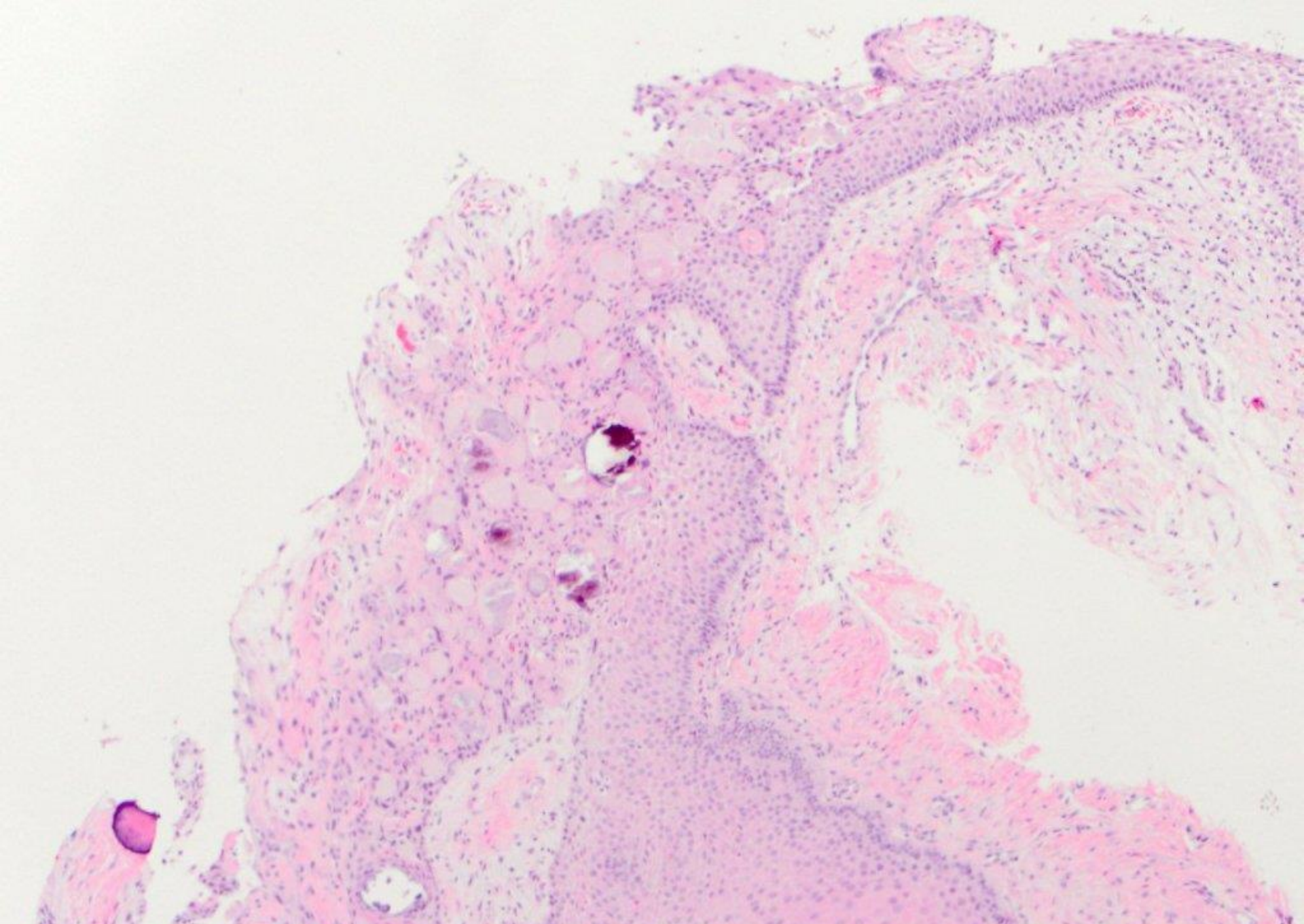


glandular odontogenic cyst

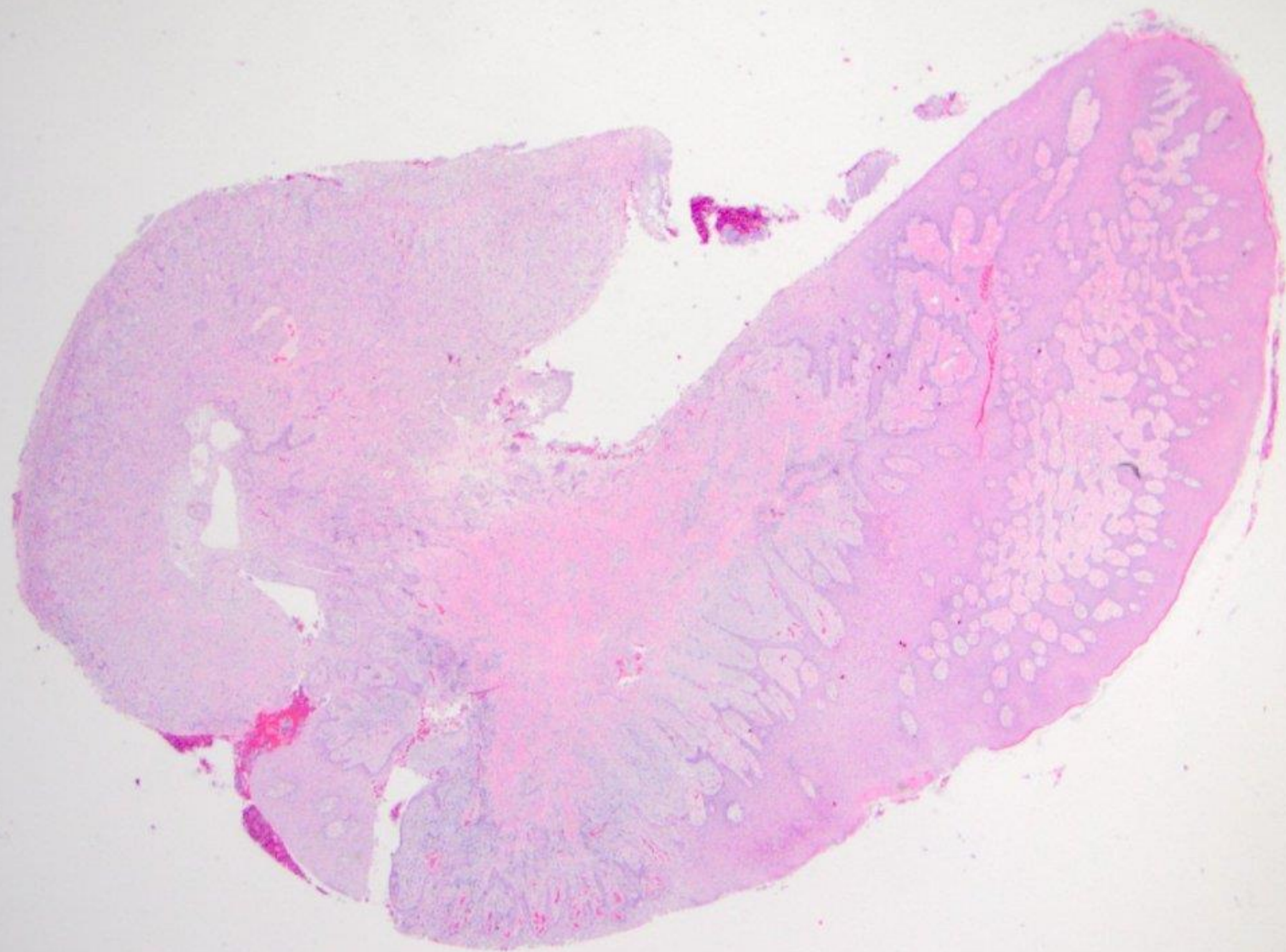


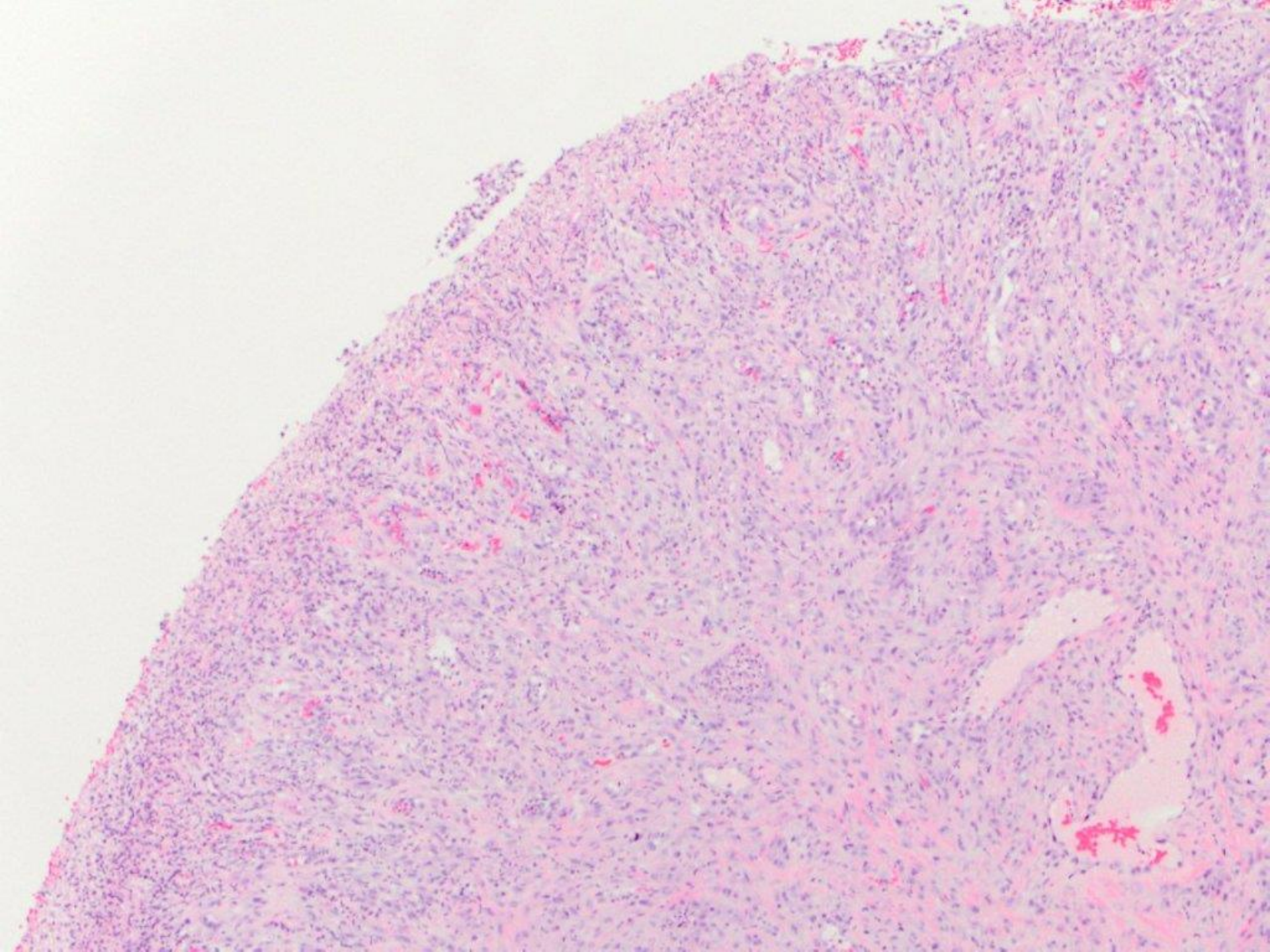
radiolucency, posterior mandible

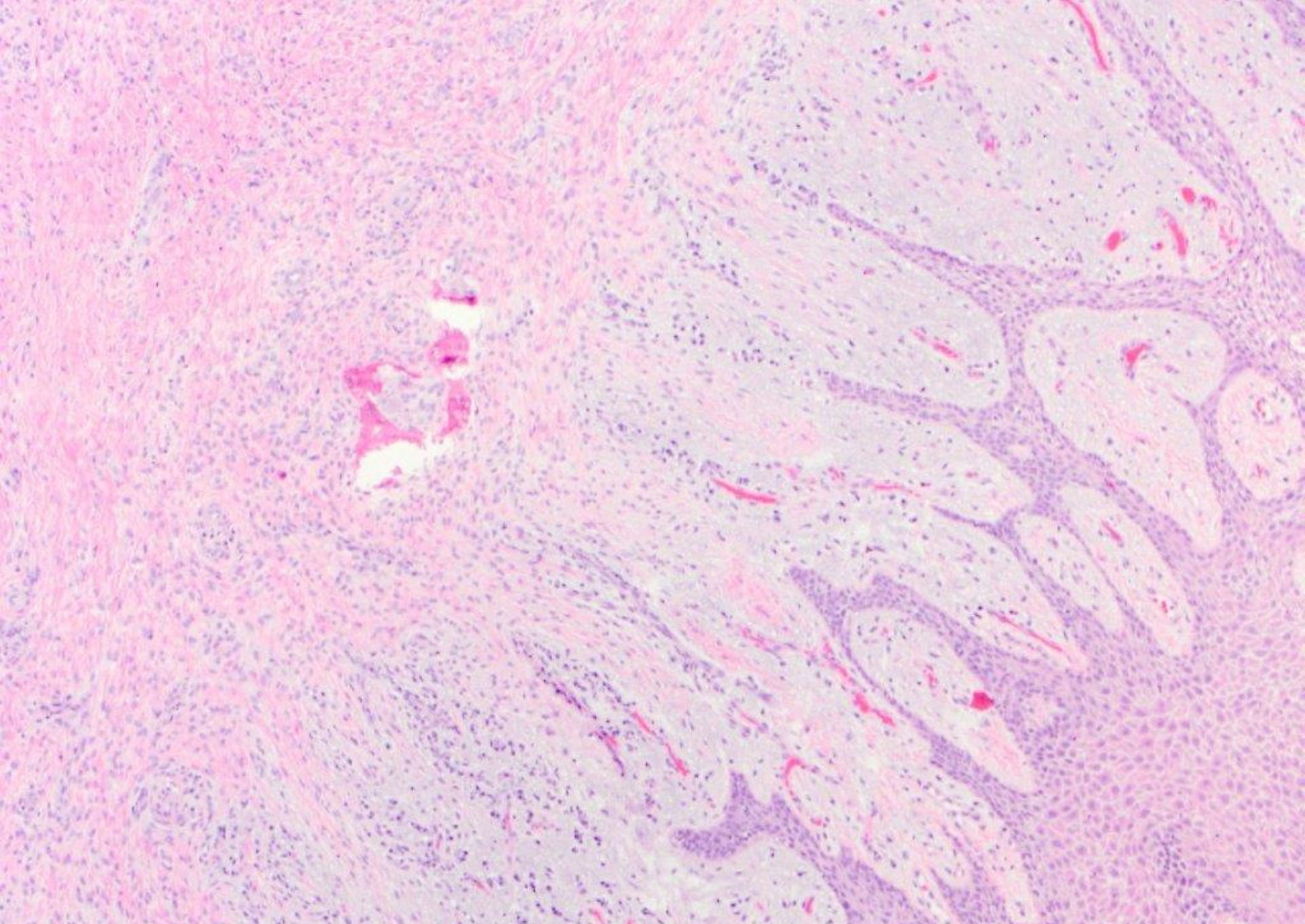




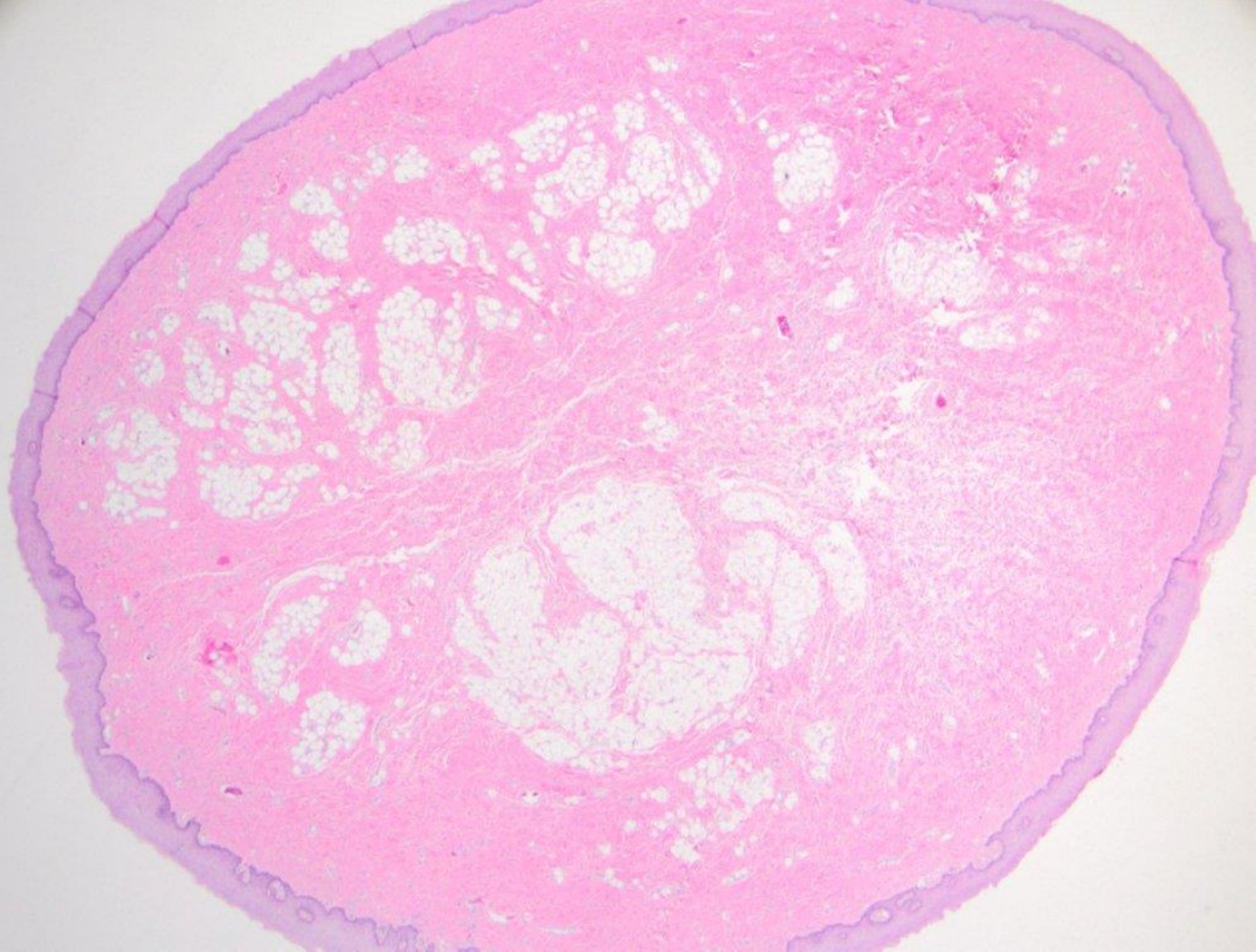
dentigerous cyst (consideration given to calcifying epithelial odontogenic tumor)

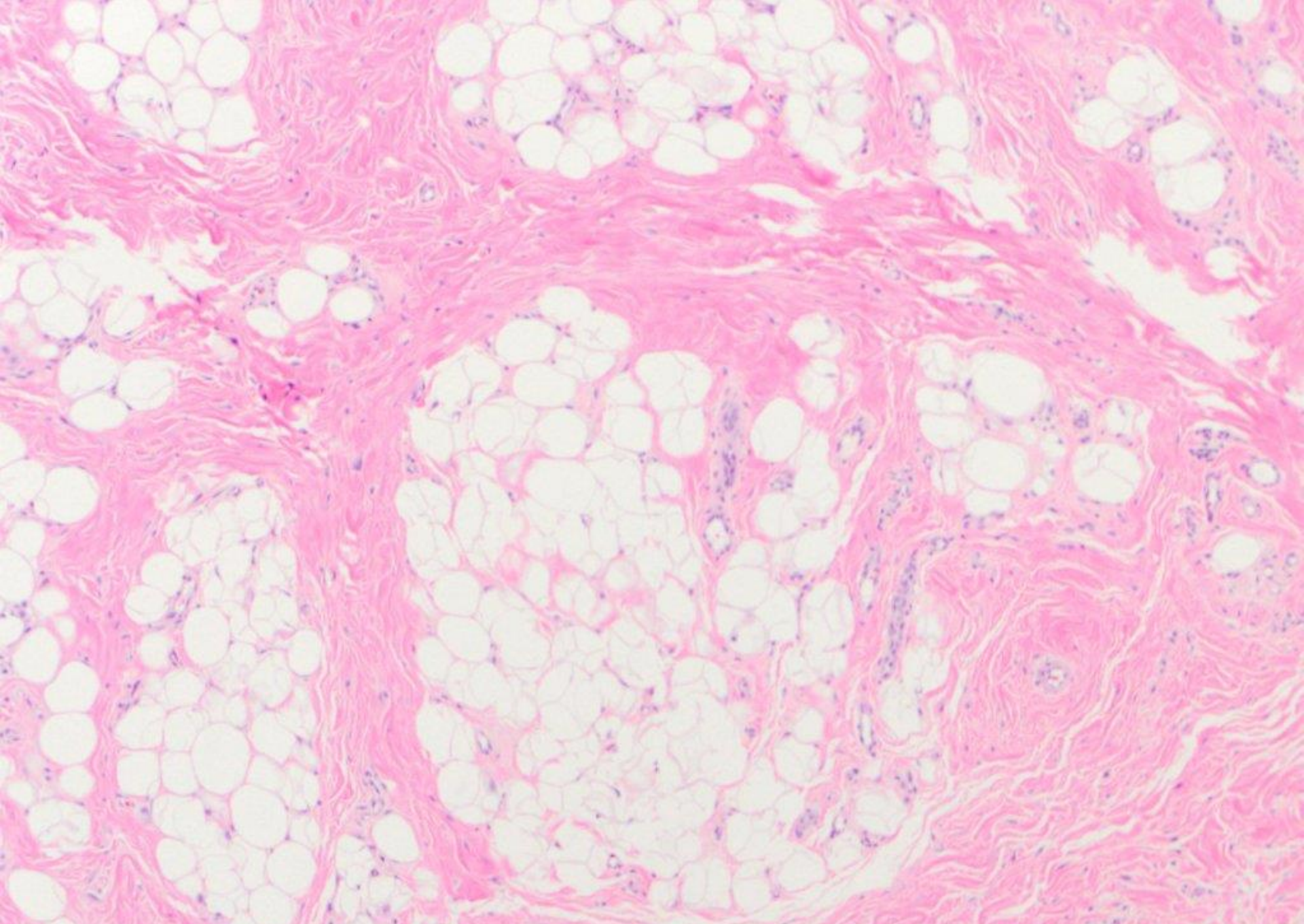




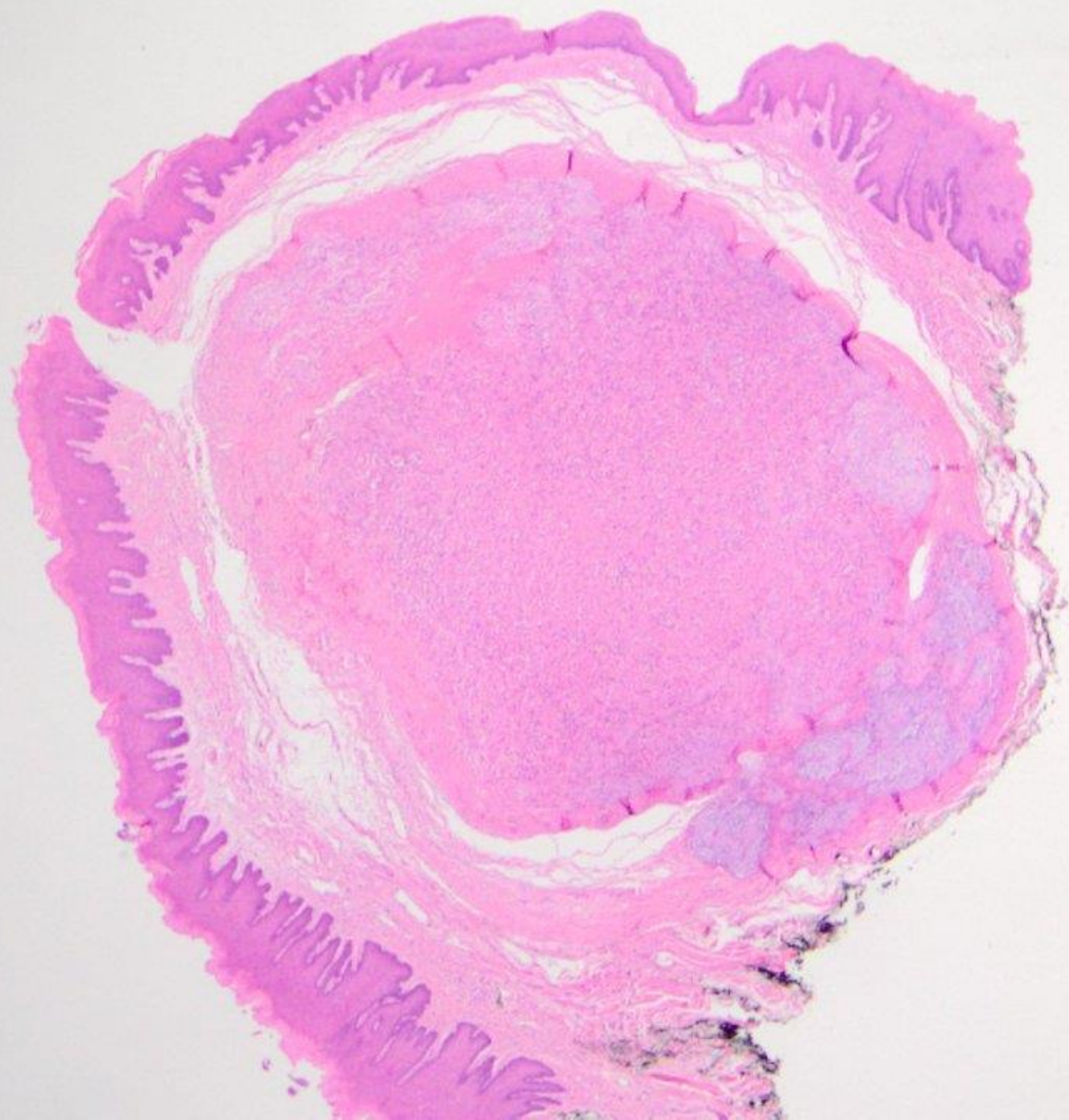


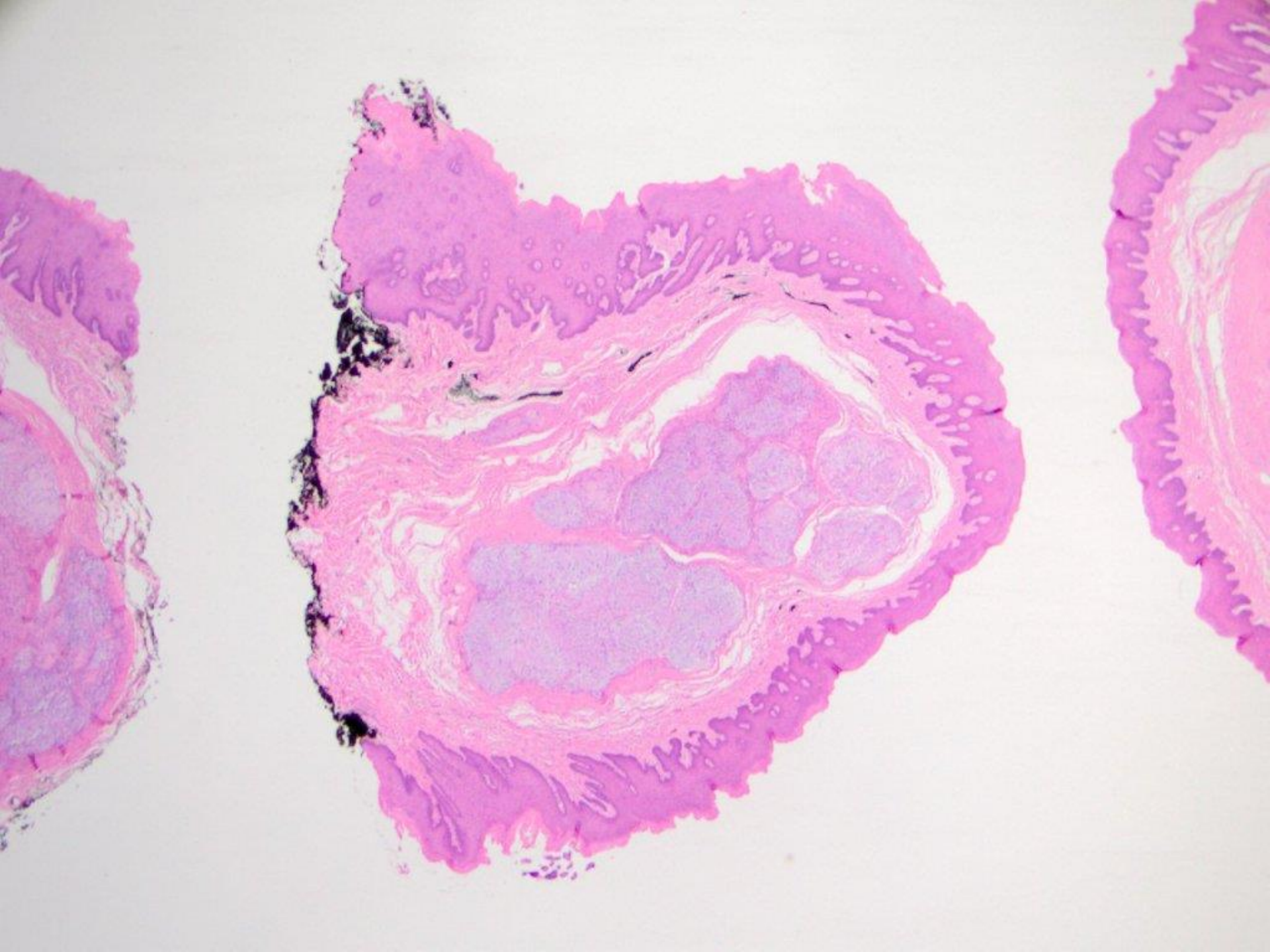
ulcerated peripheral ossifying fibroma

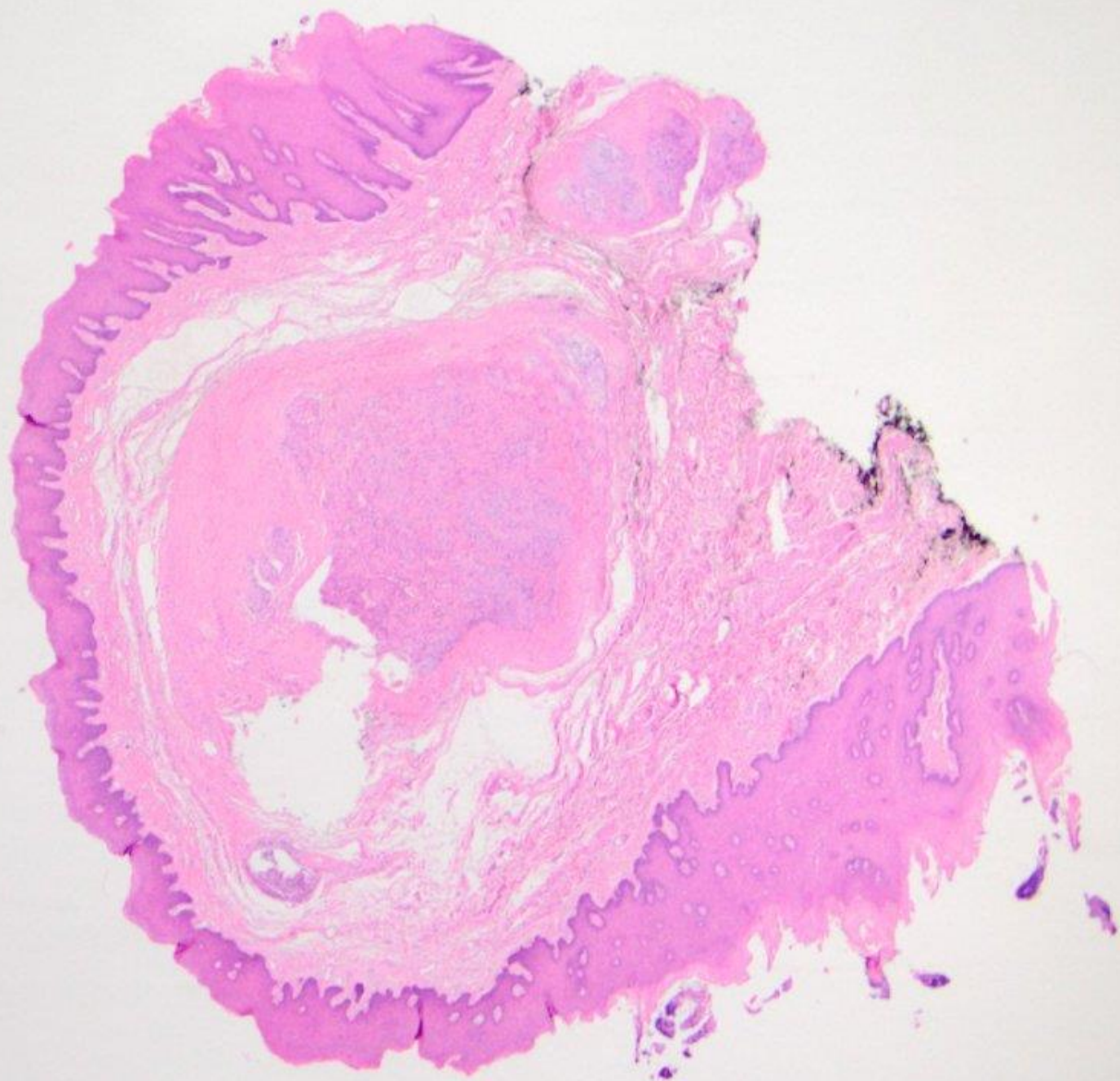
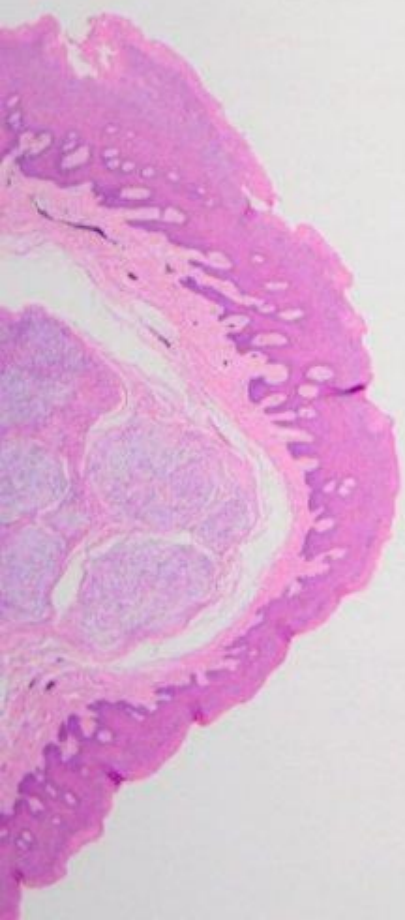


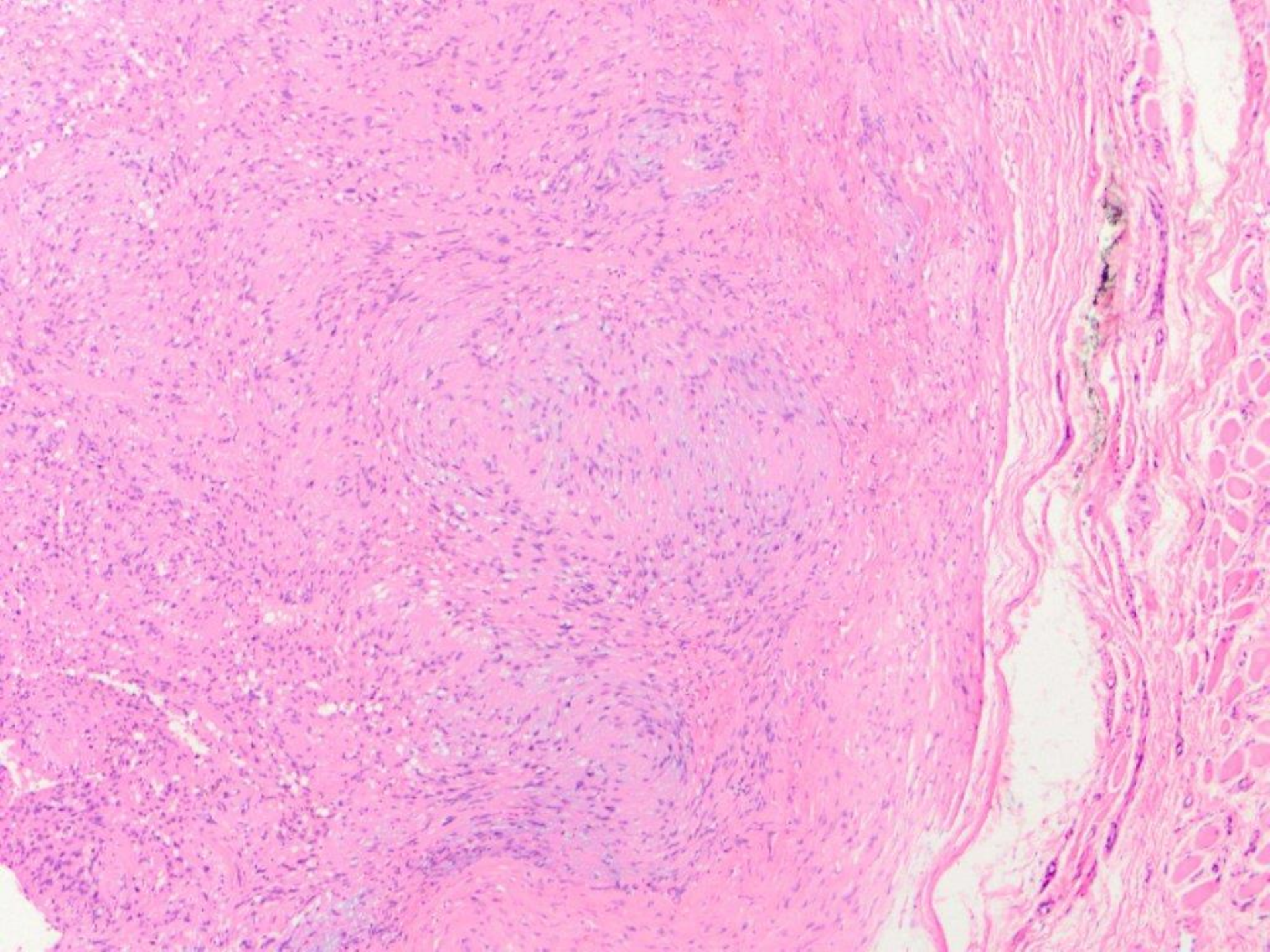


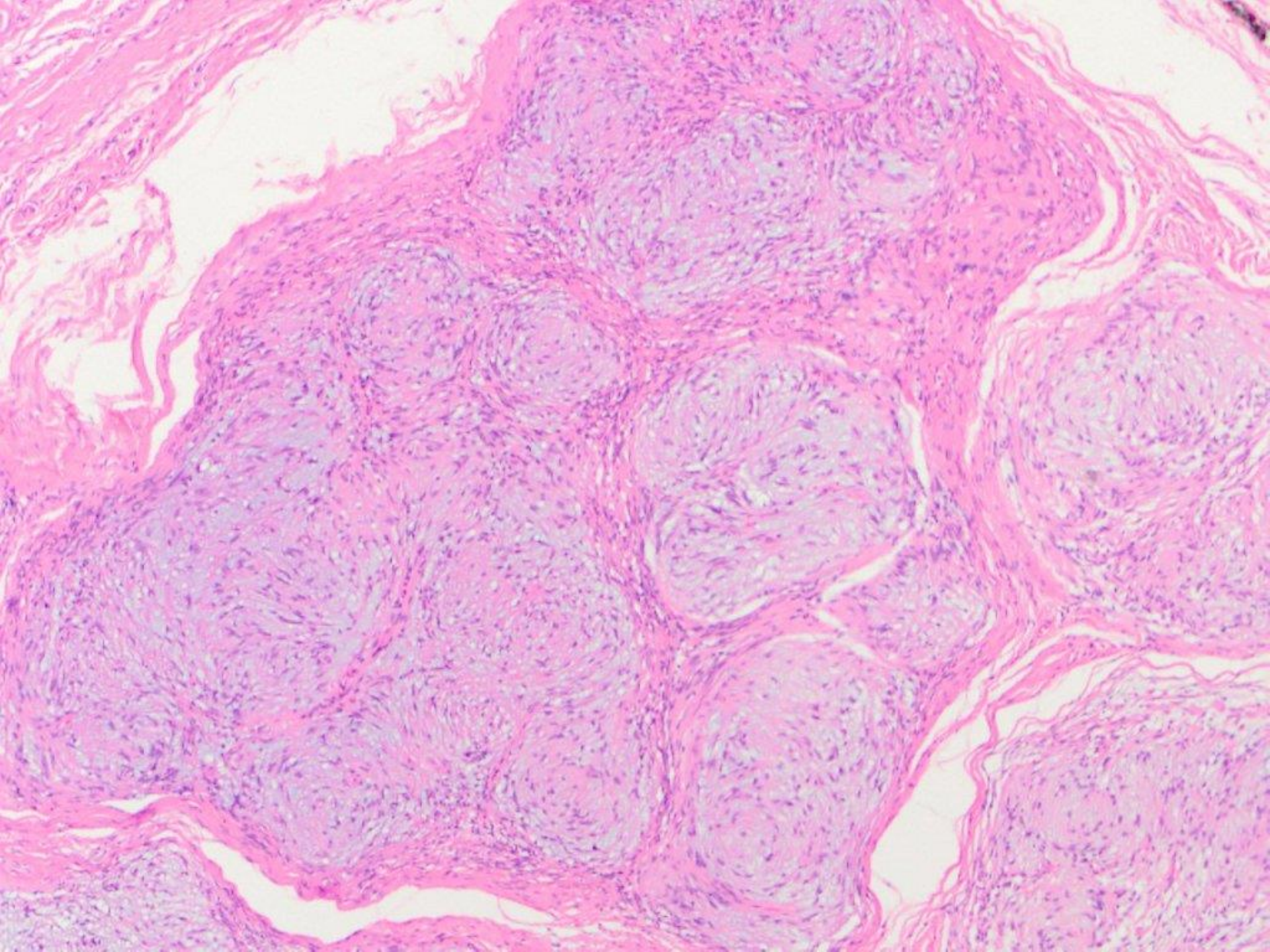
fibrolipoma

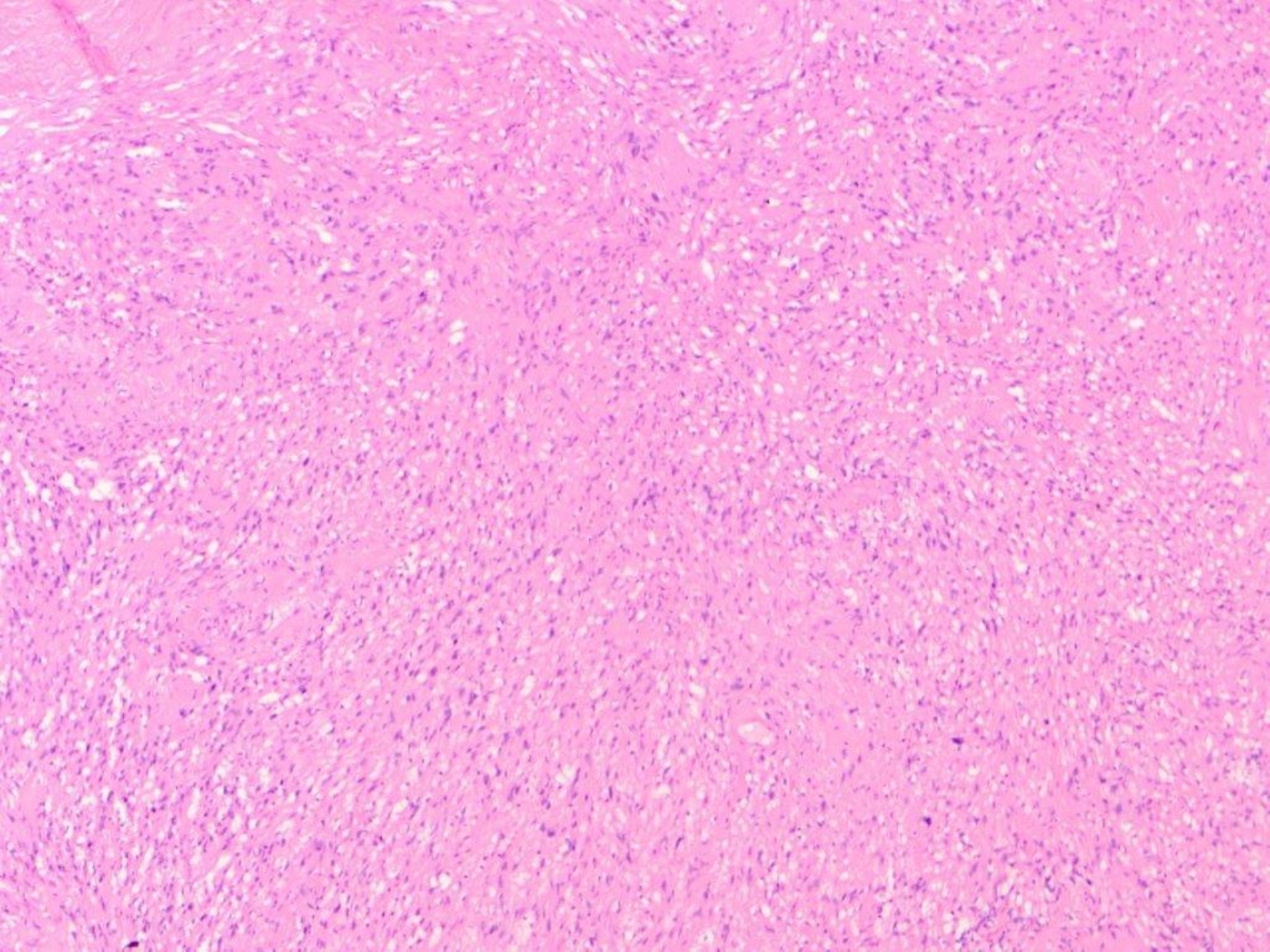


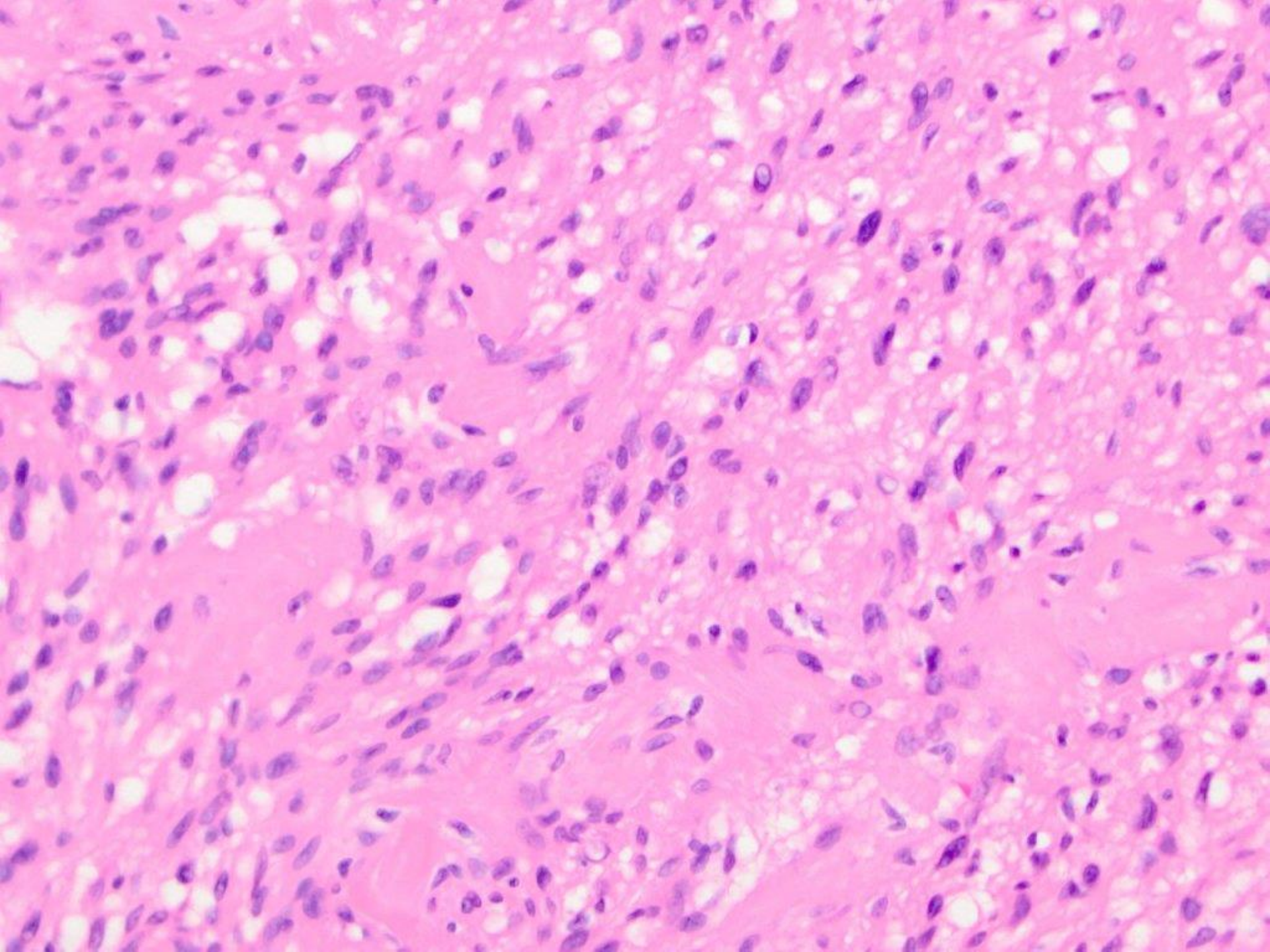


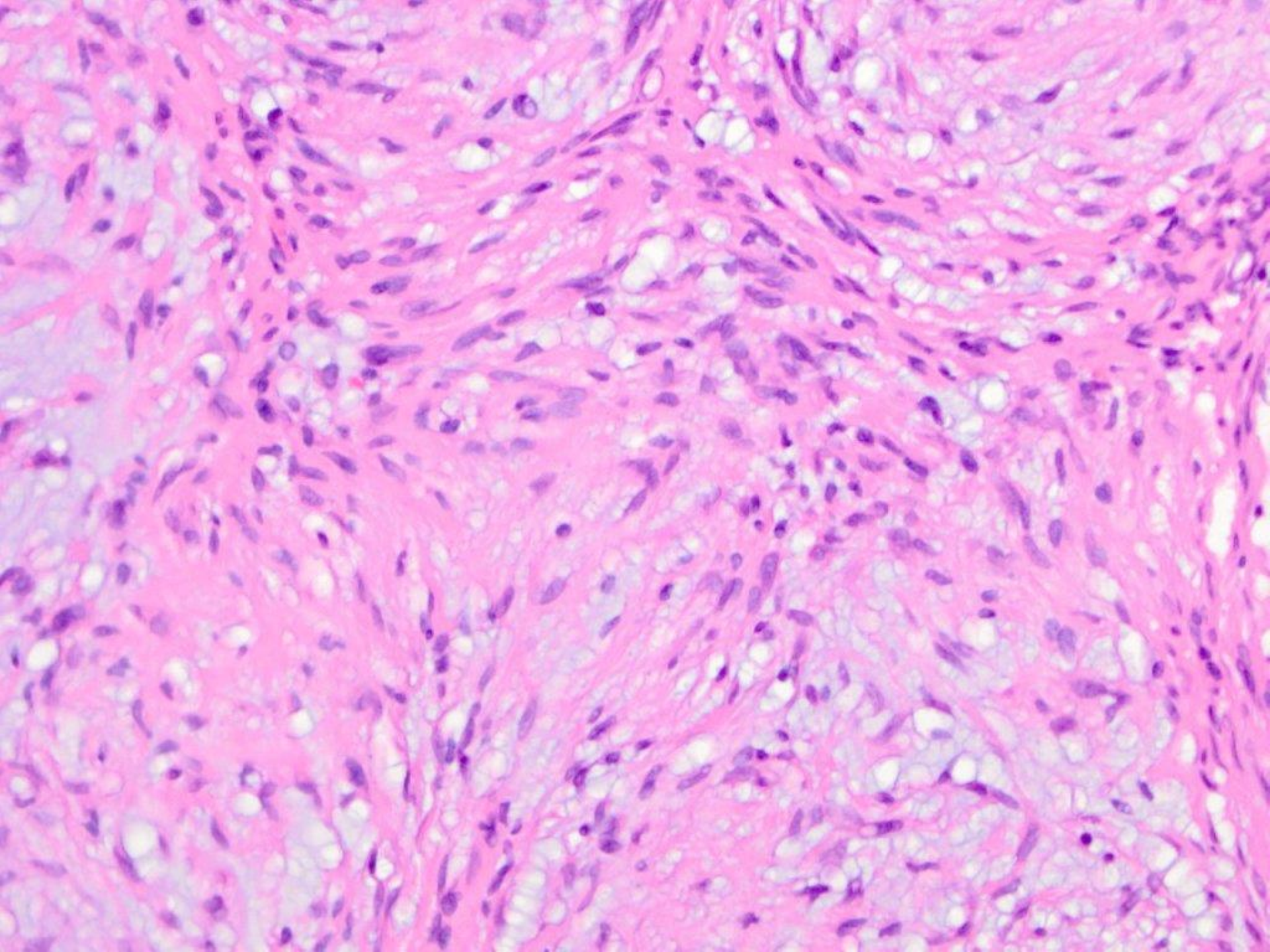


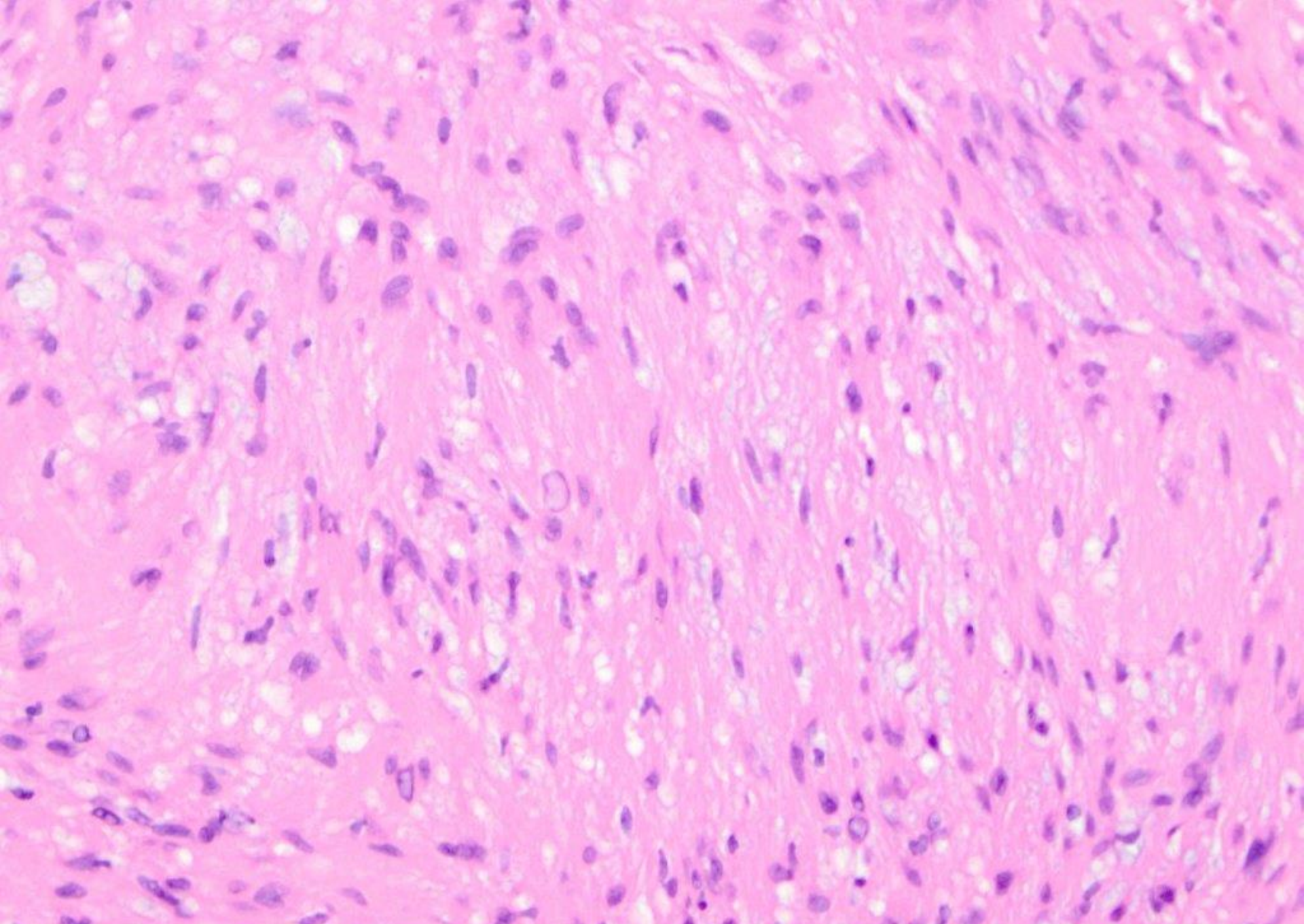




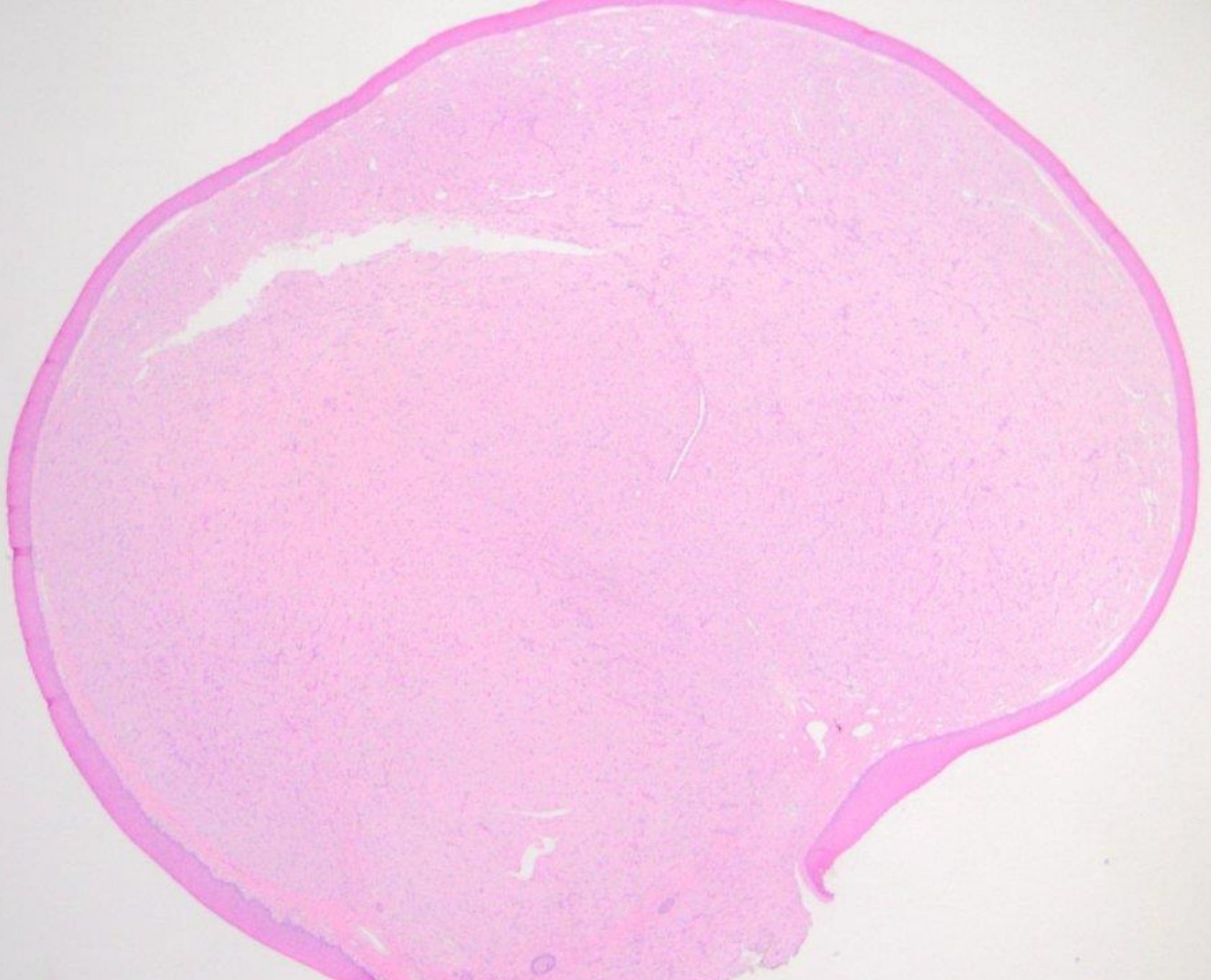




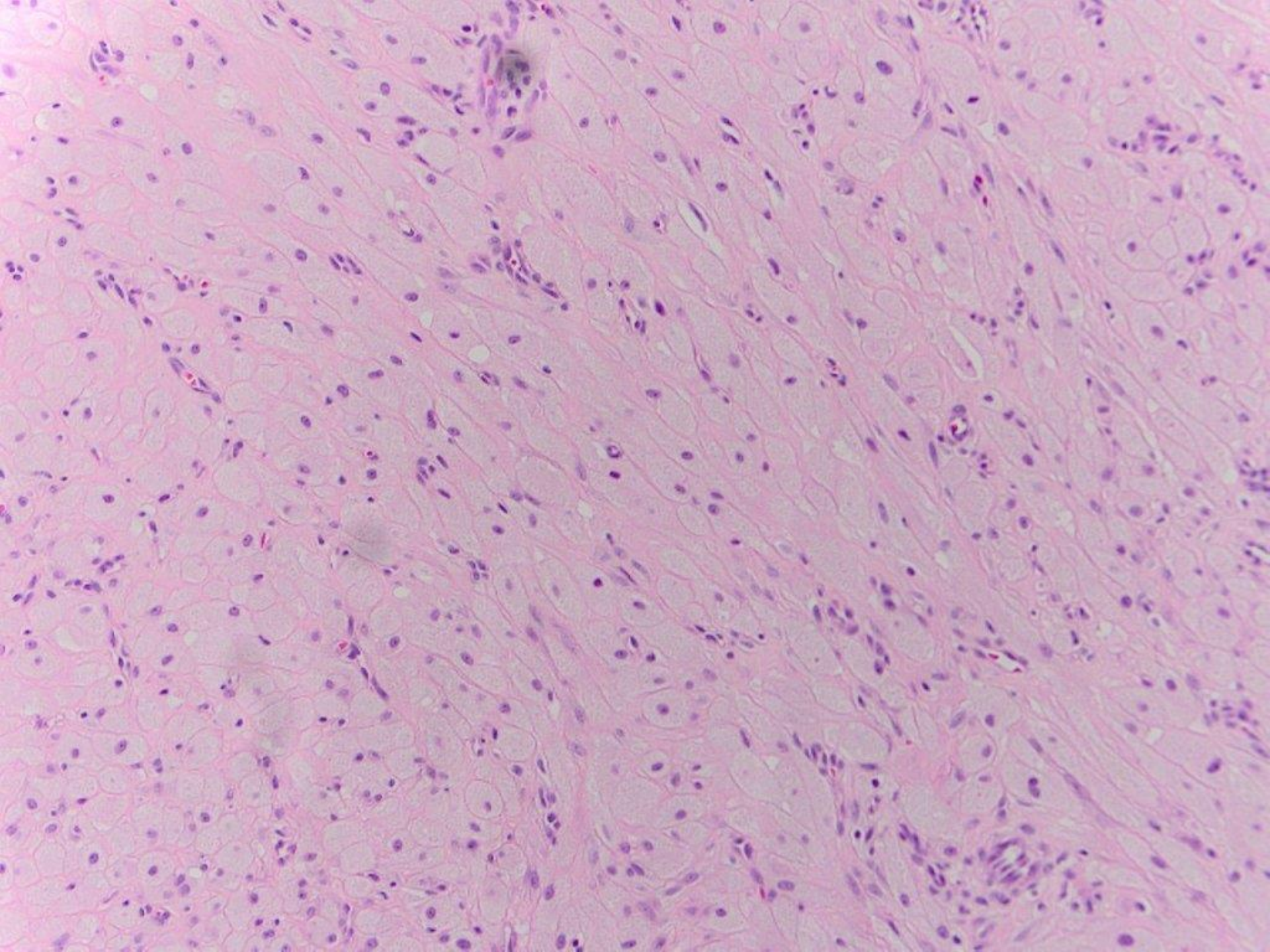


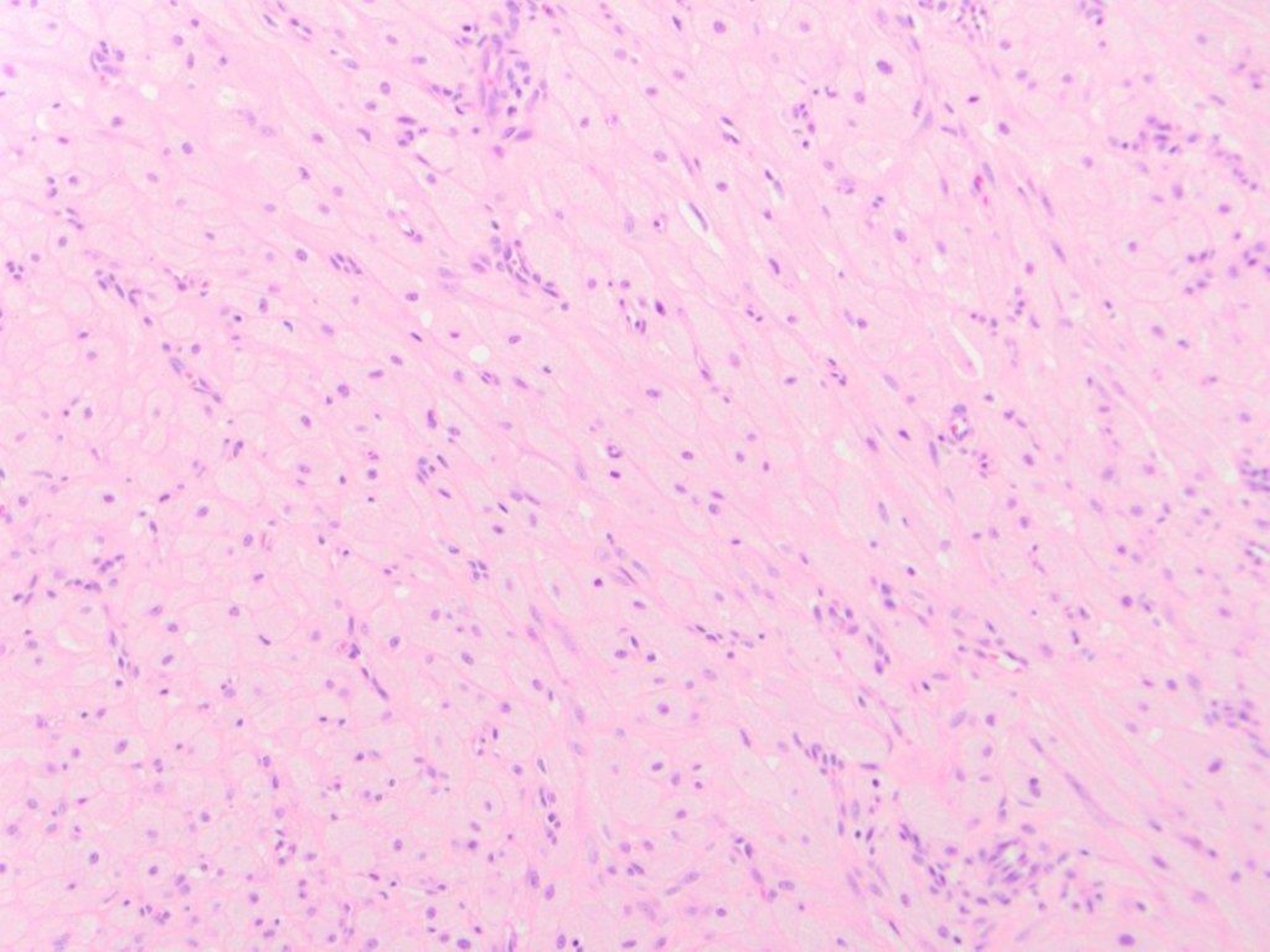


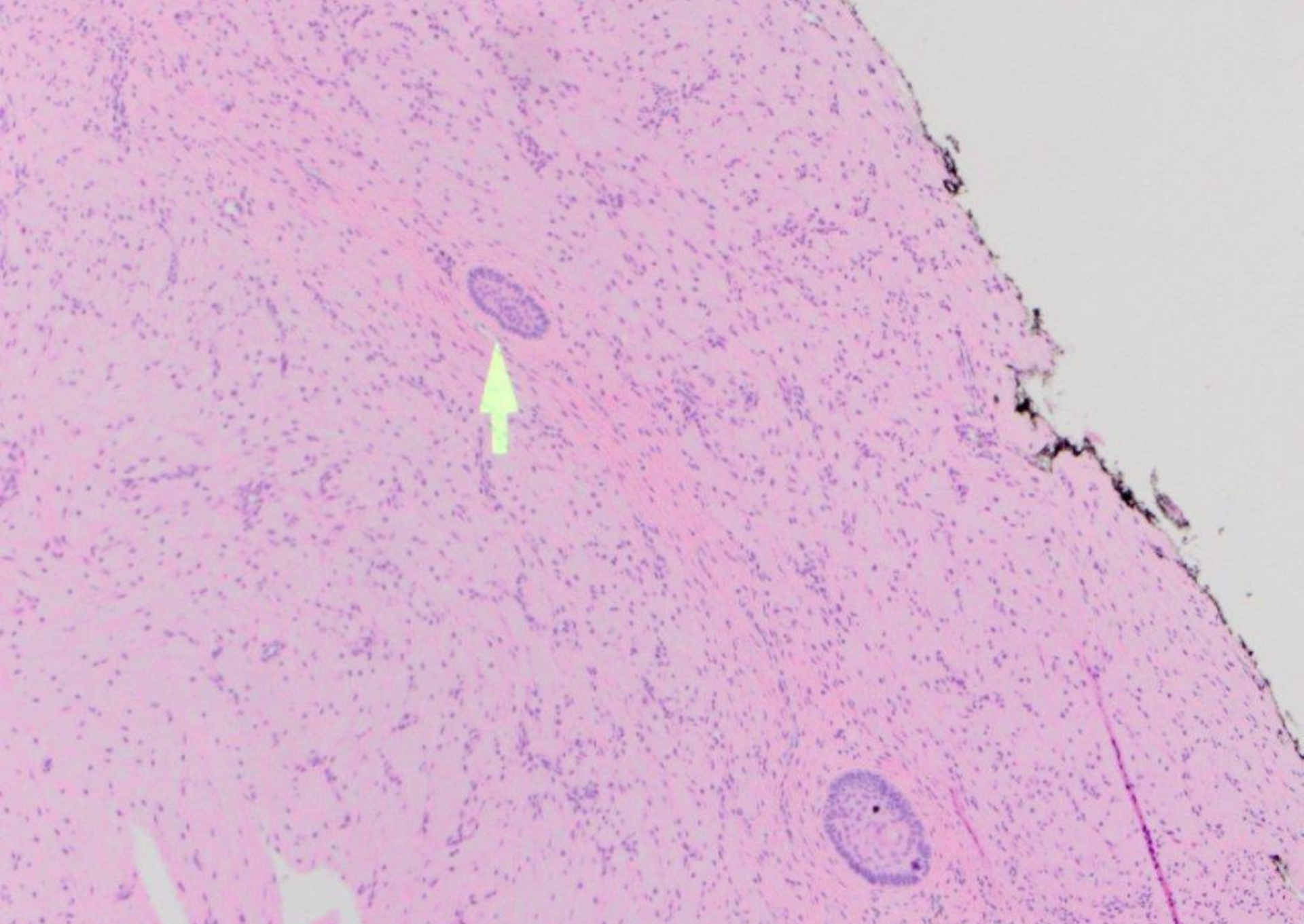
plexiform schwannoma



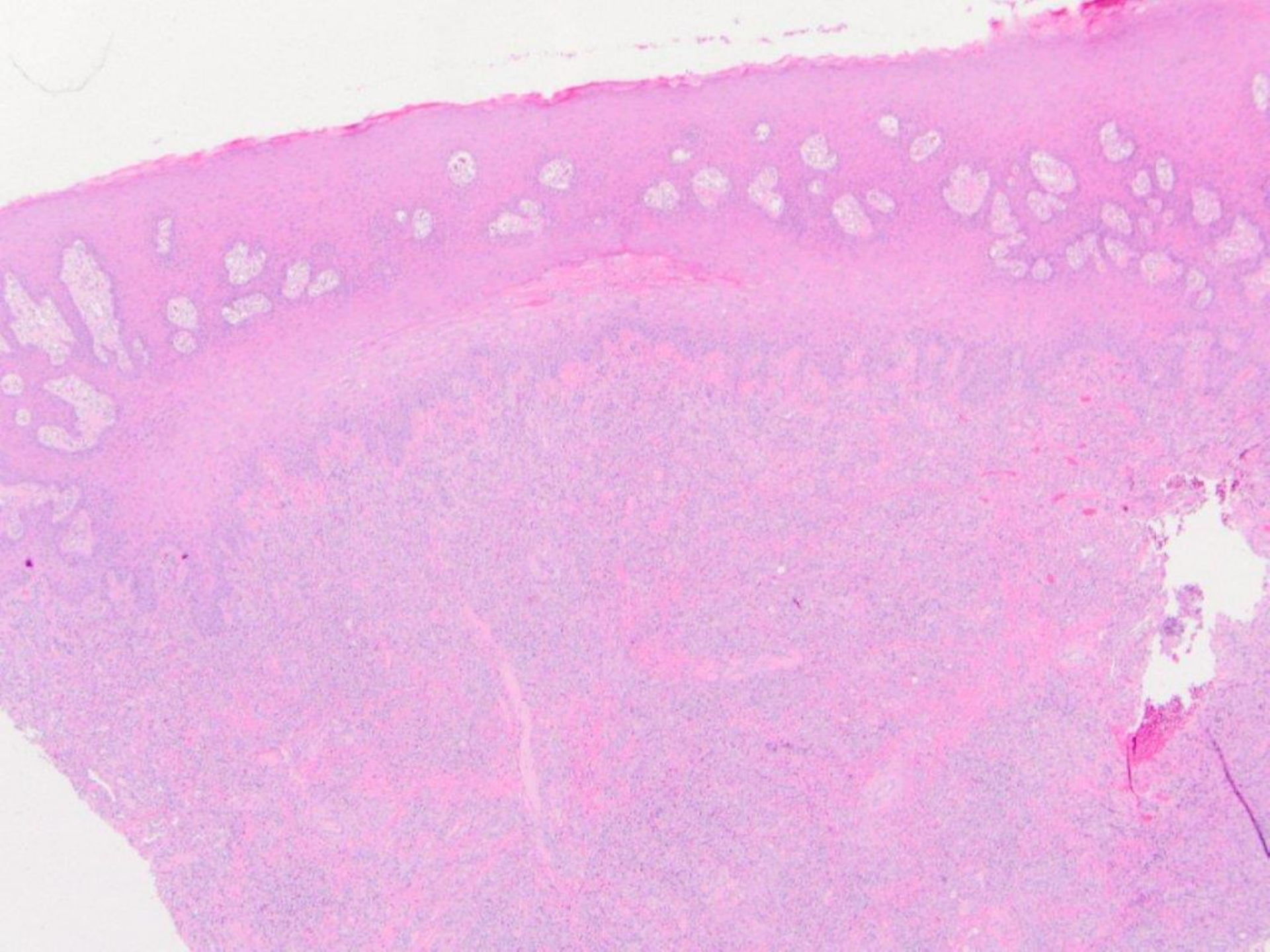
nodule, palate of 2-day-old

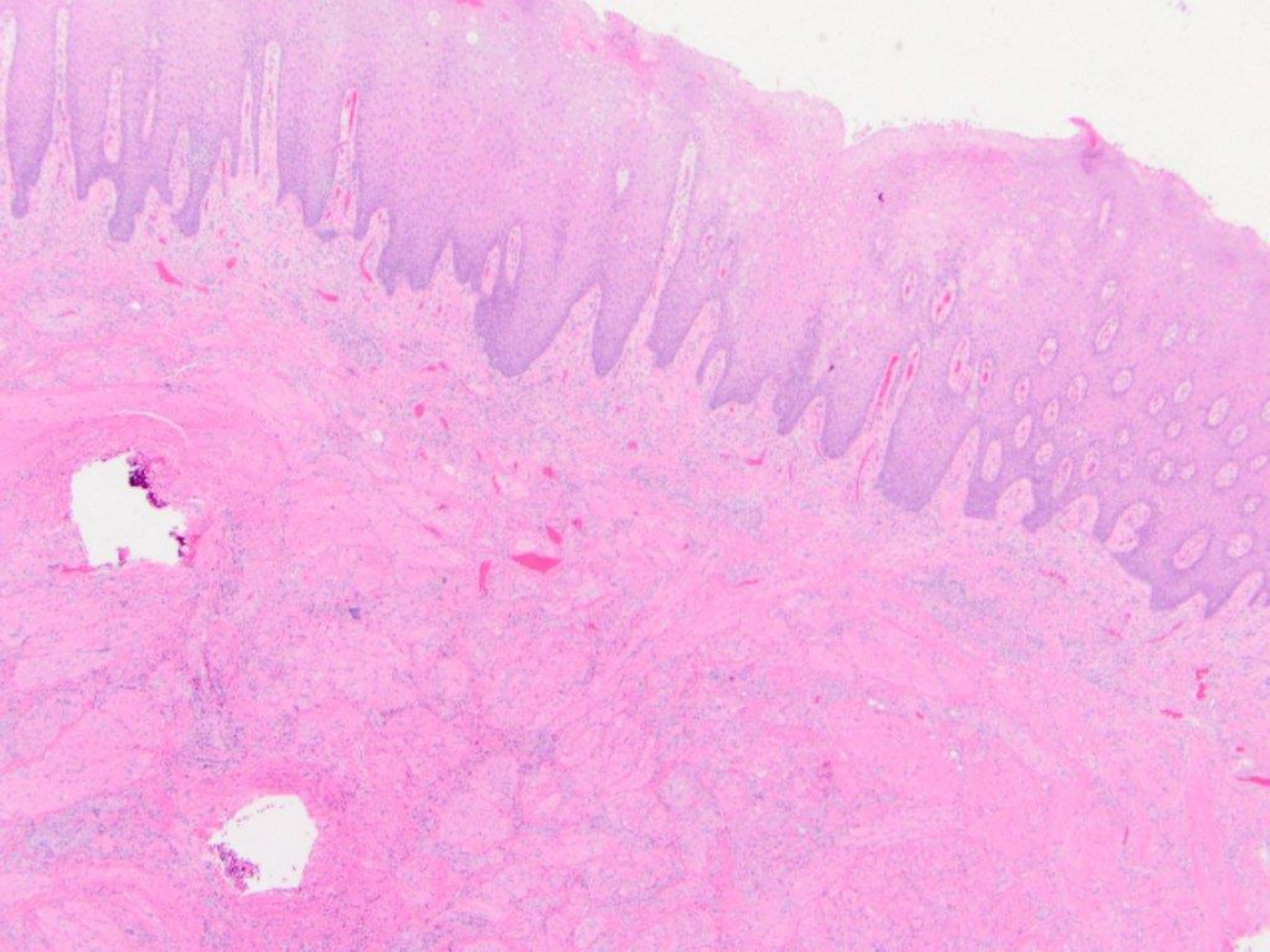


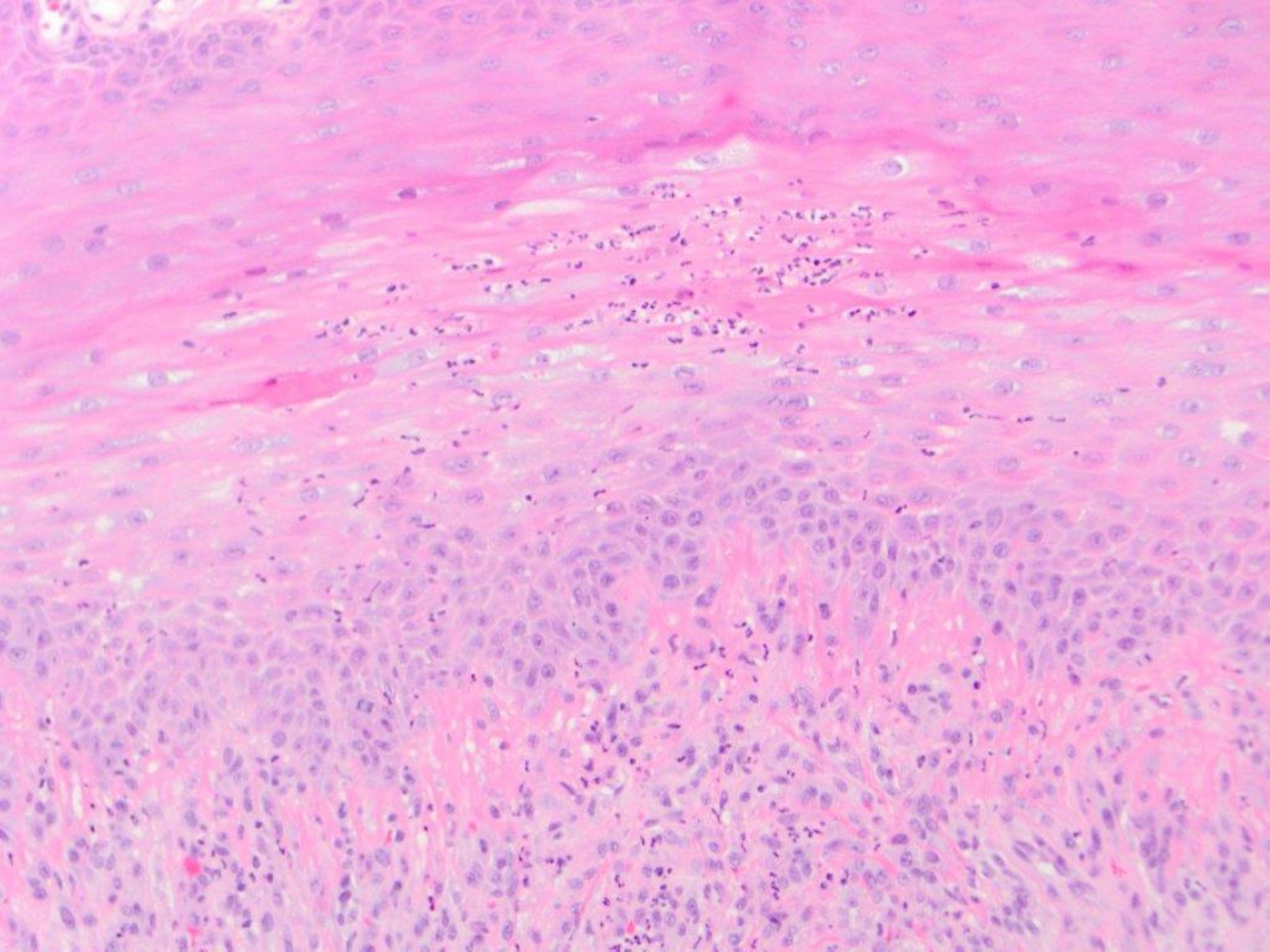


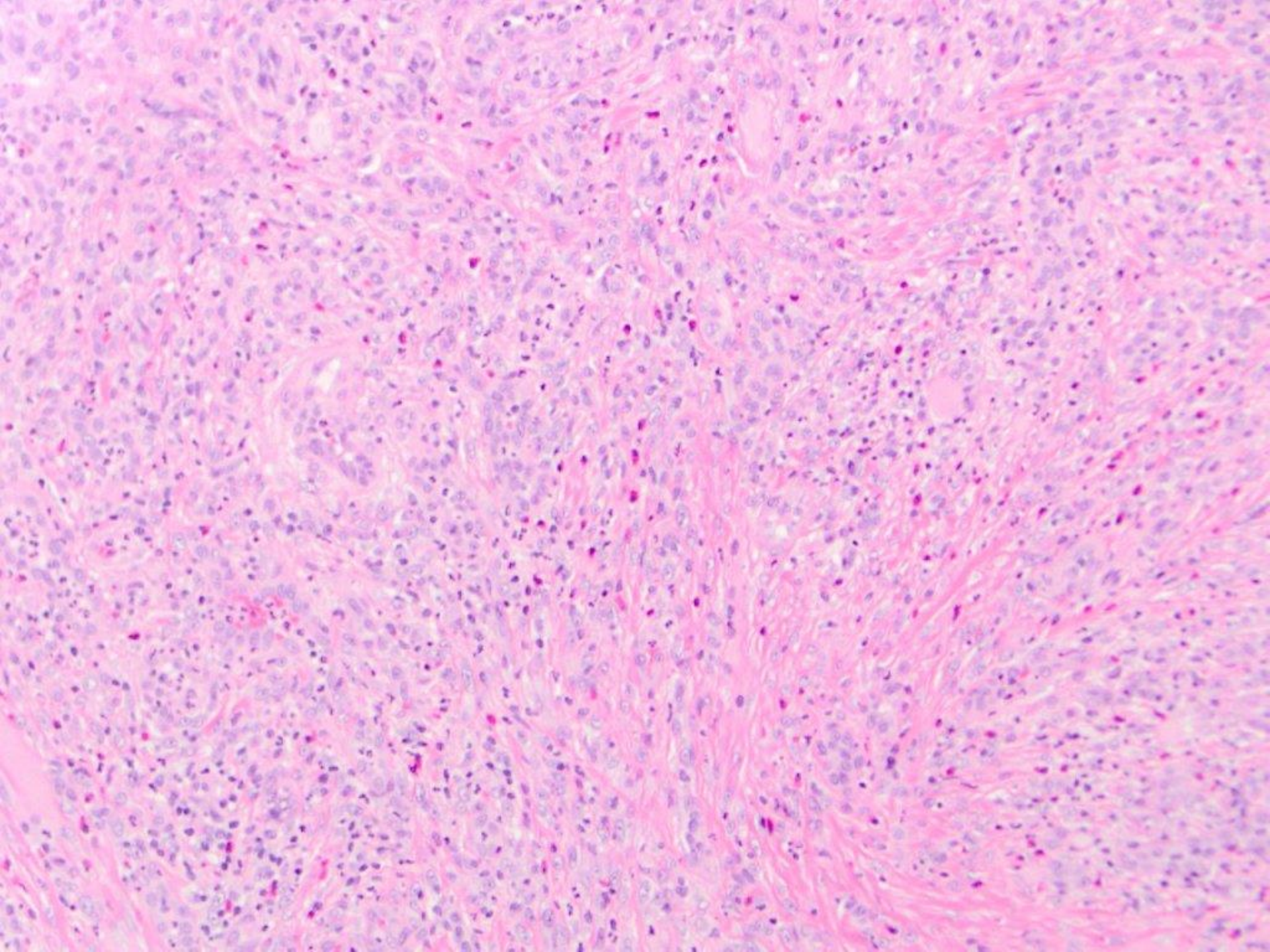


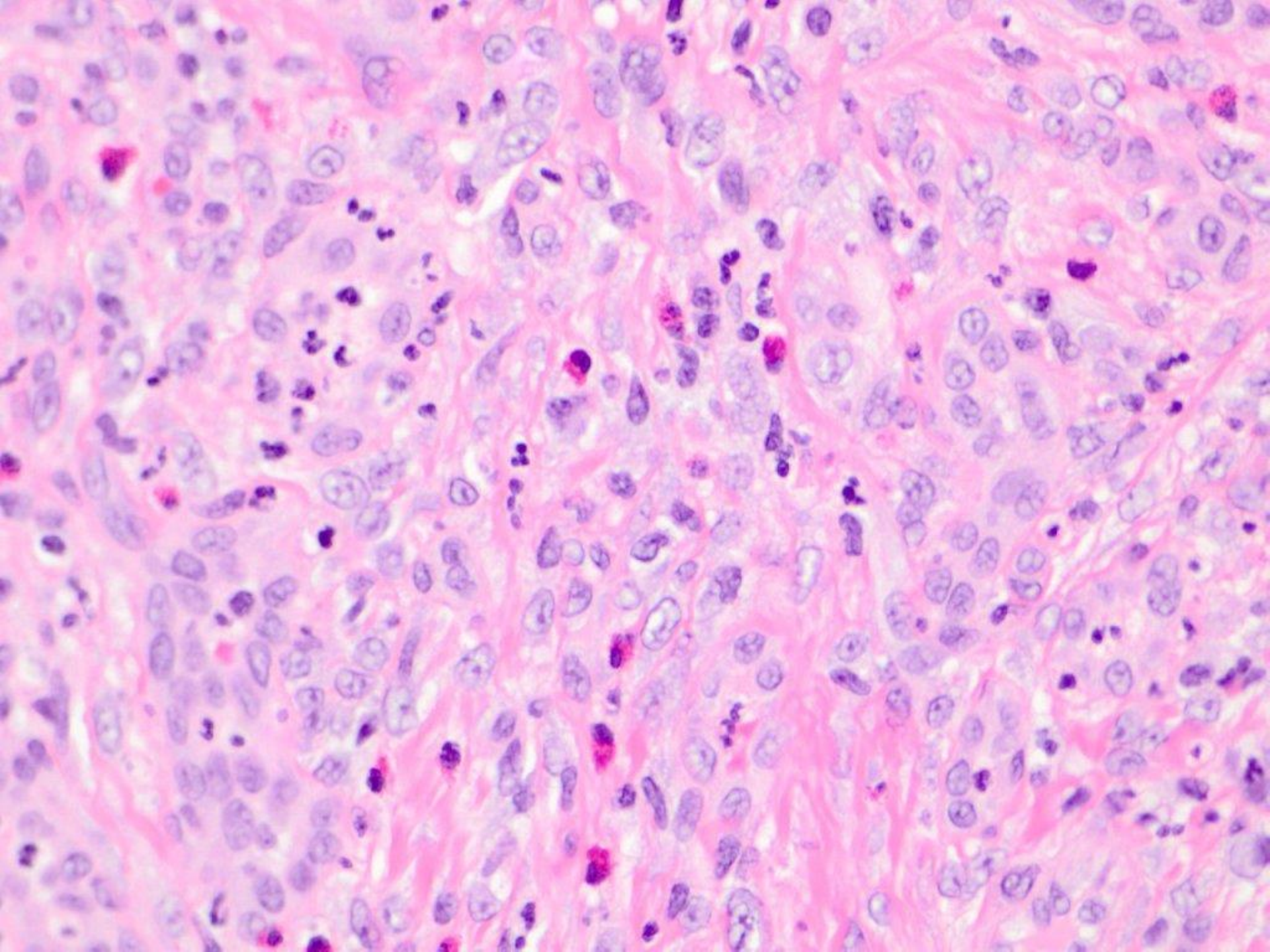
congenital epulis of the newborn

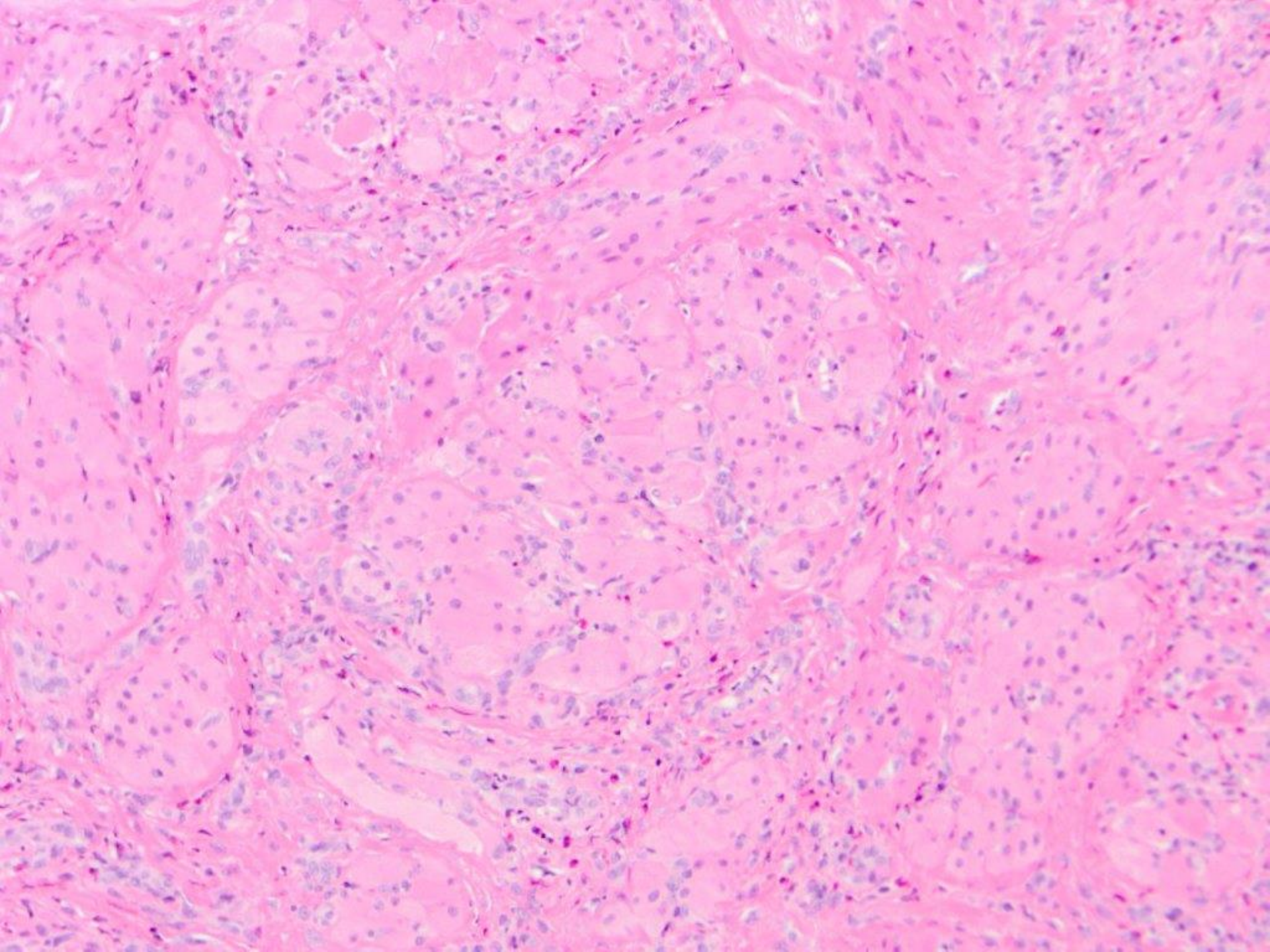


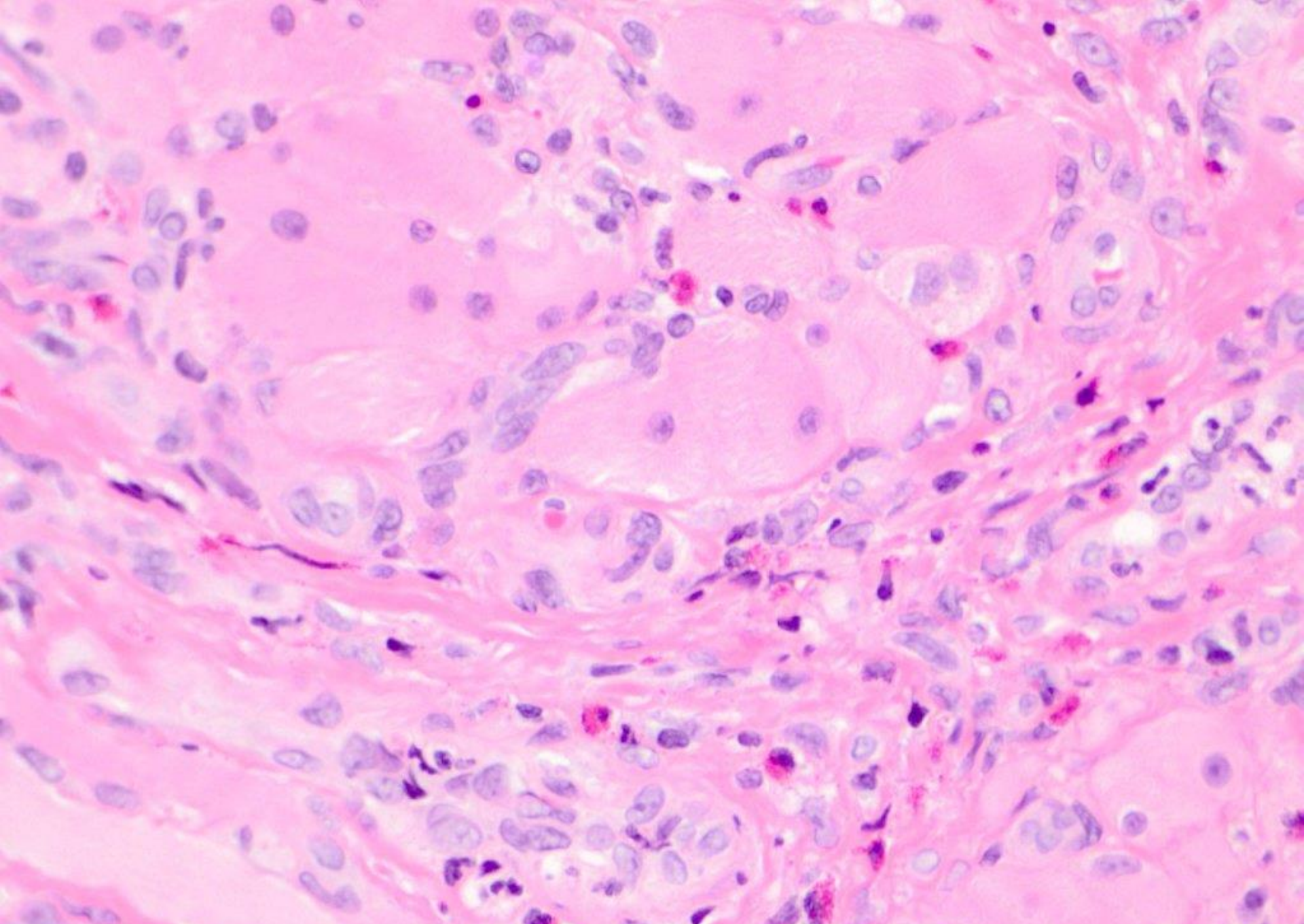




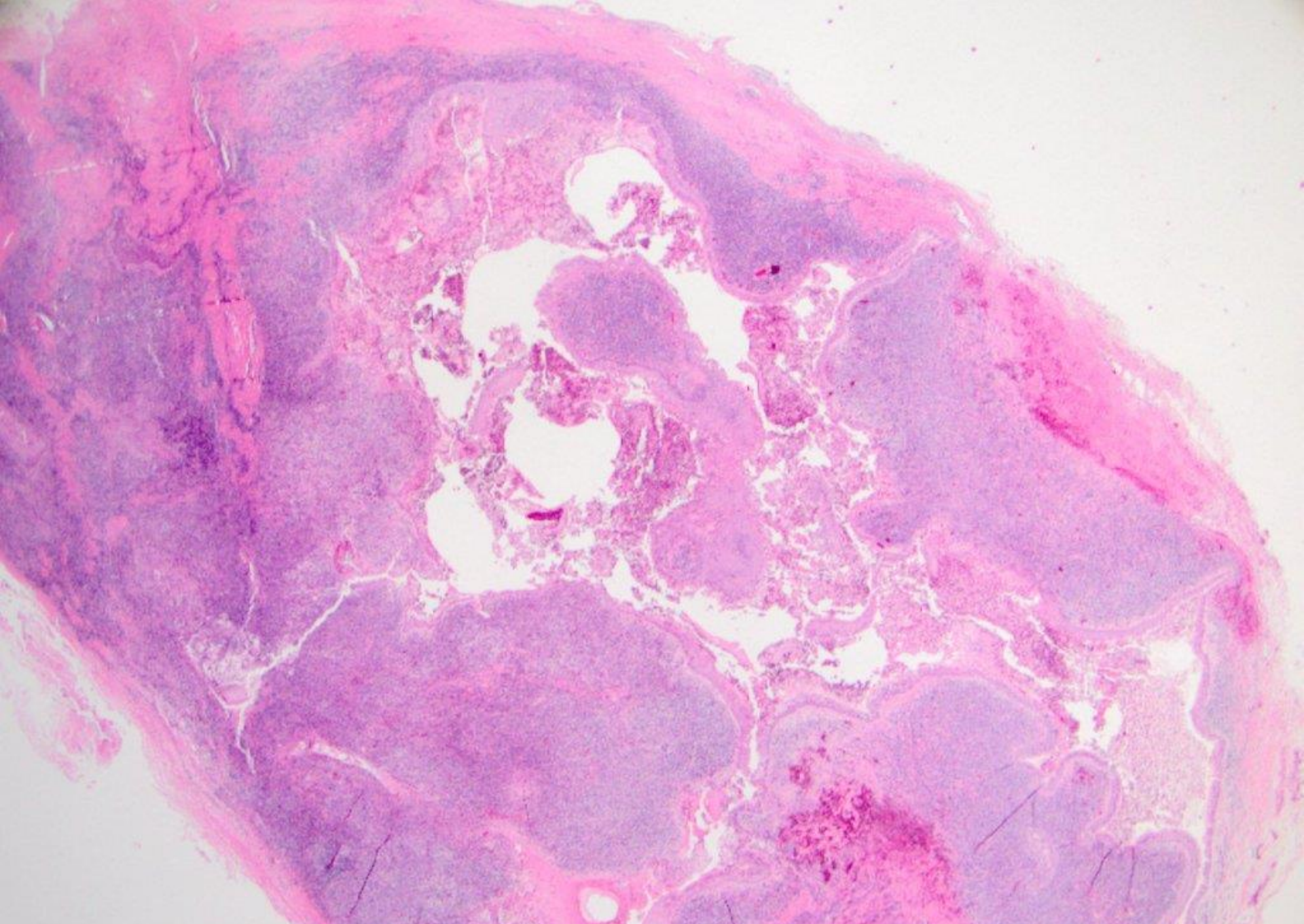




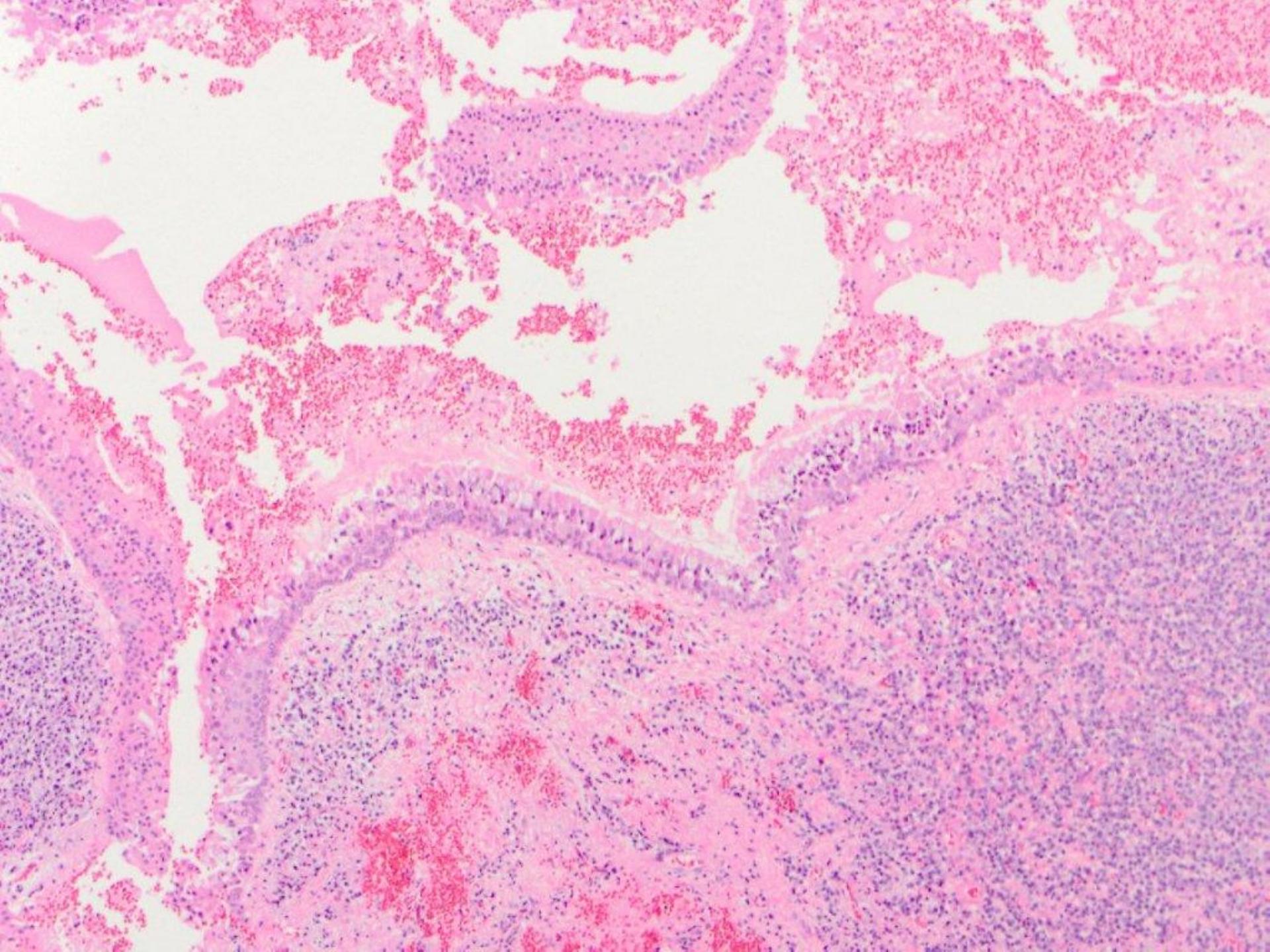


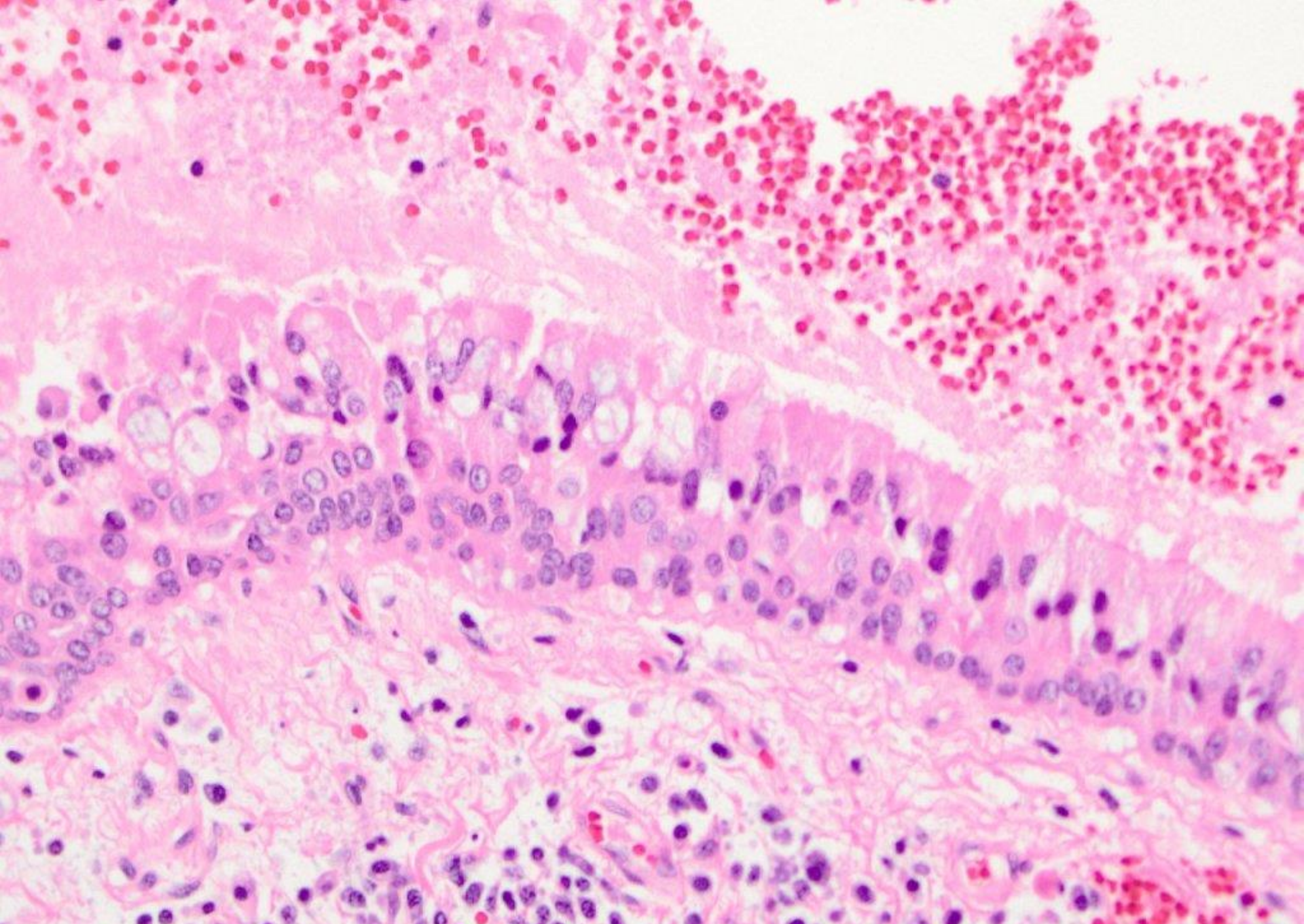


traumatic ulcerative granuloma with stromal eosinophilia (TUGSE)

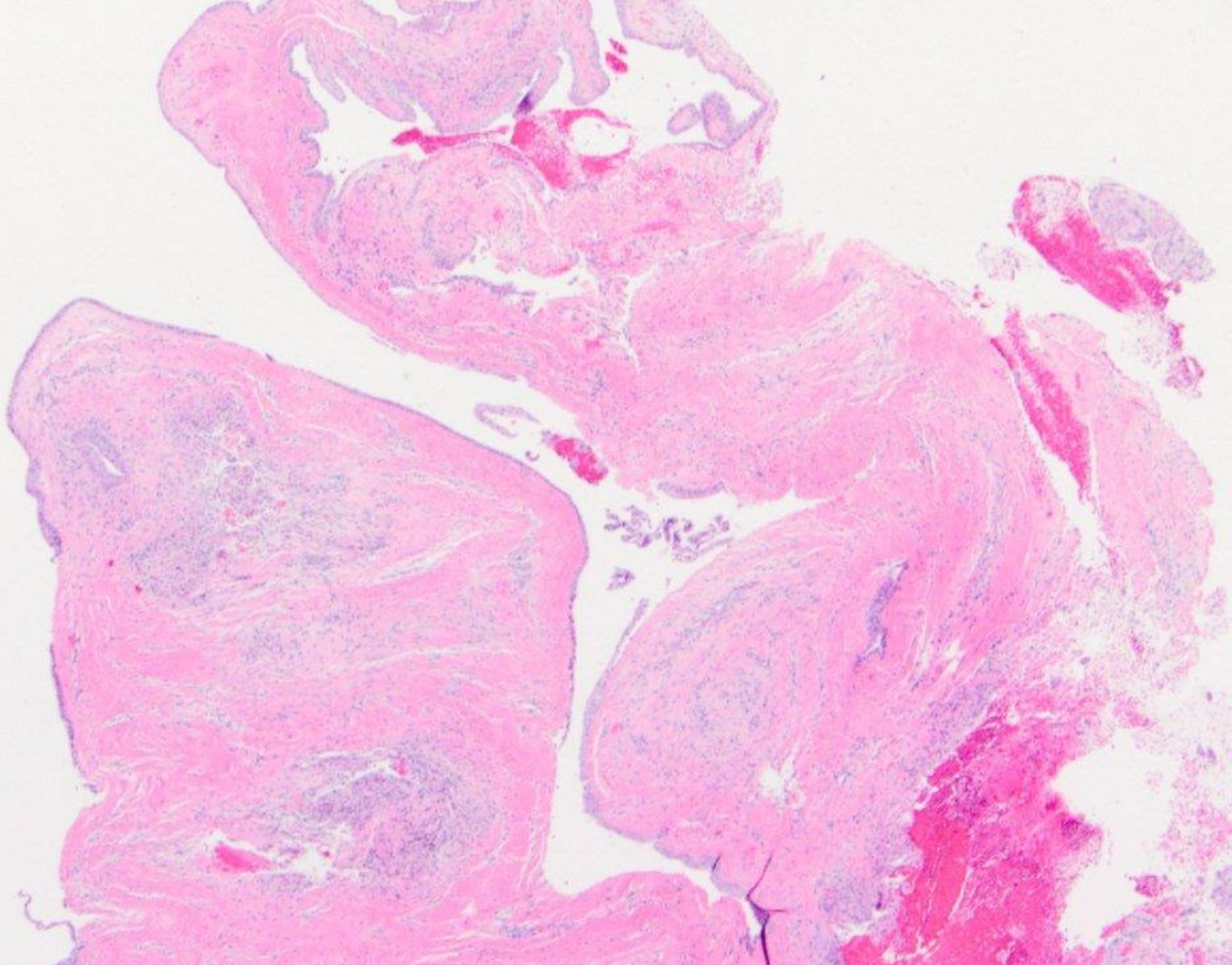


midline, anterior palate

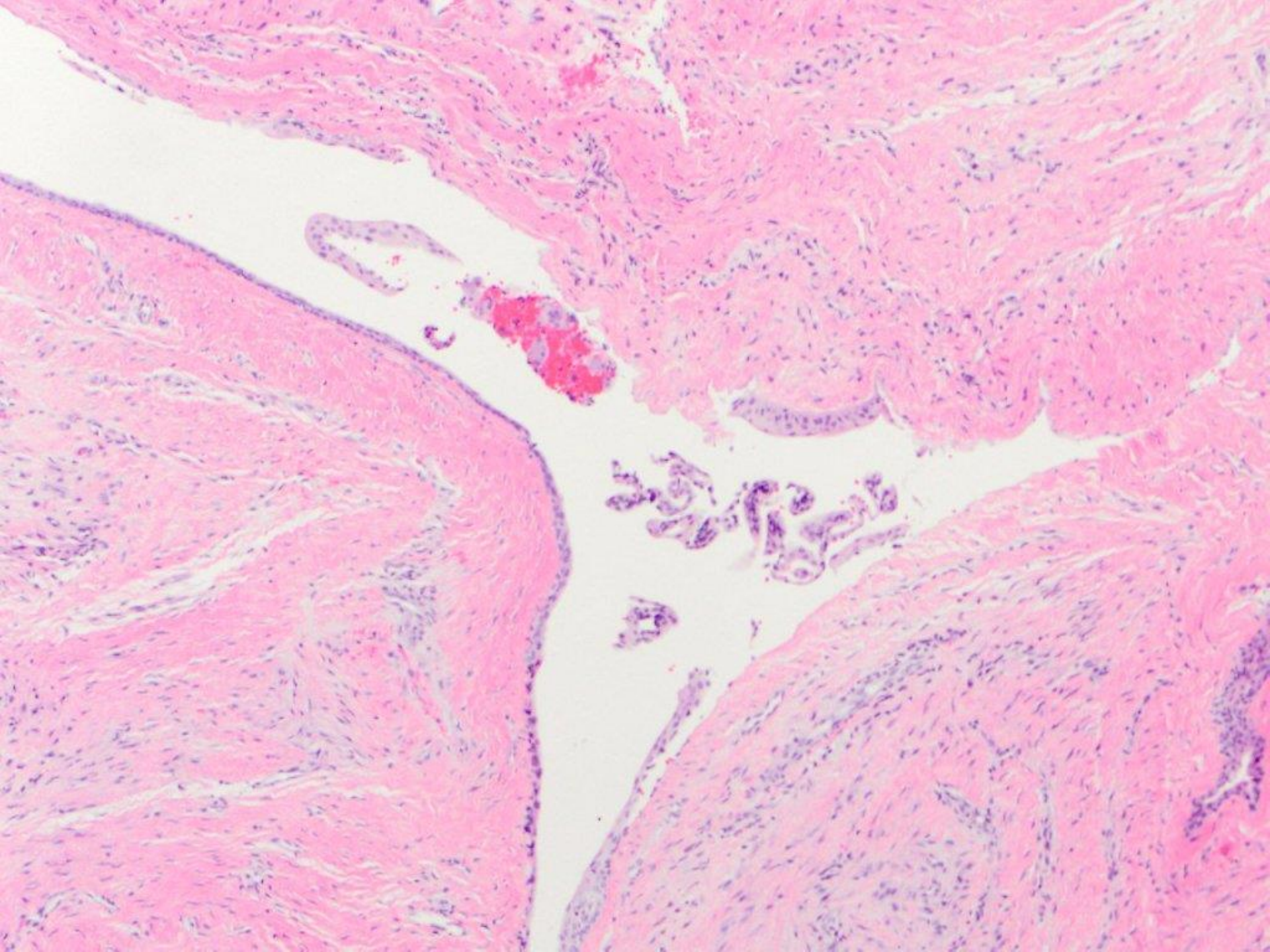


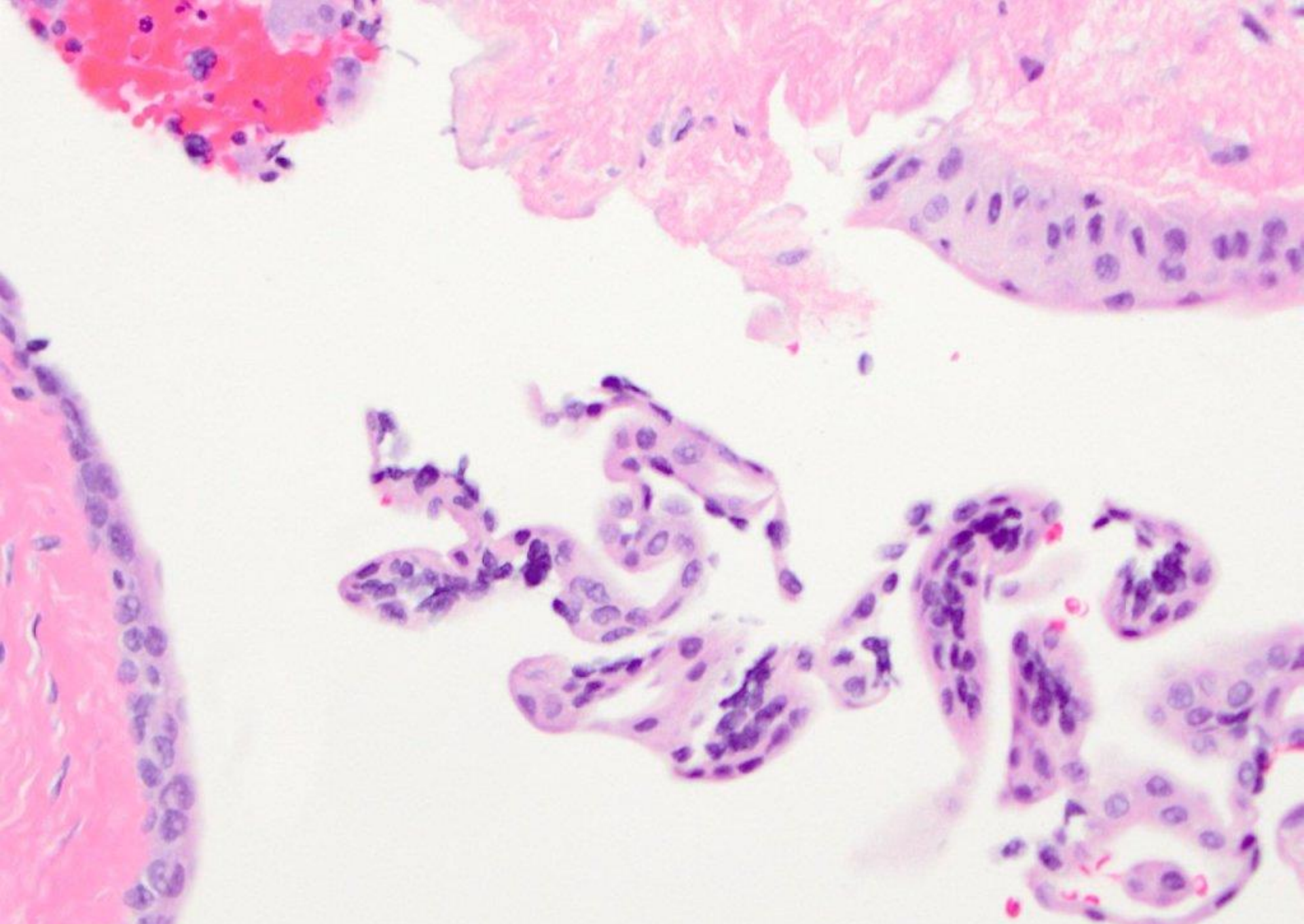


inflamed nasopalatine duct cyst

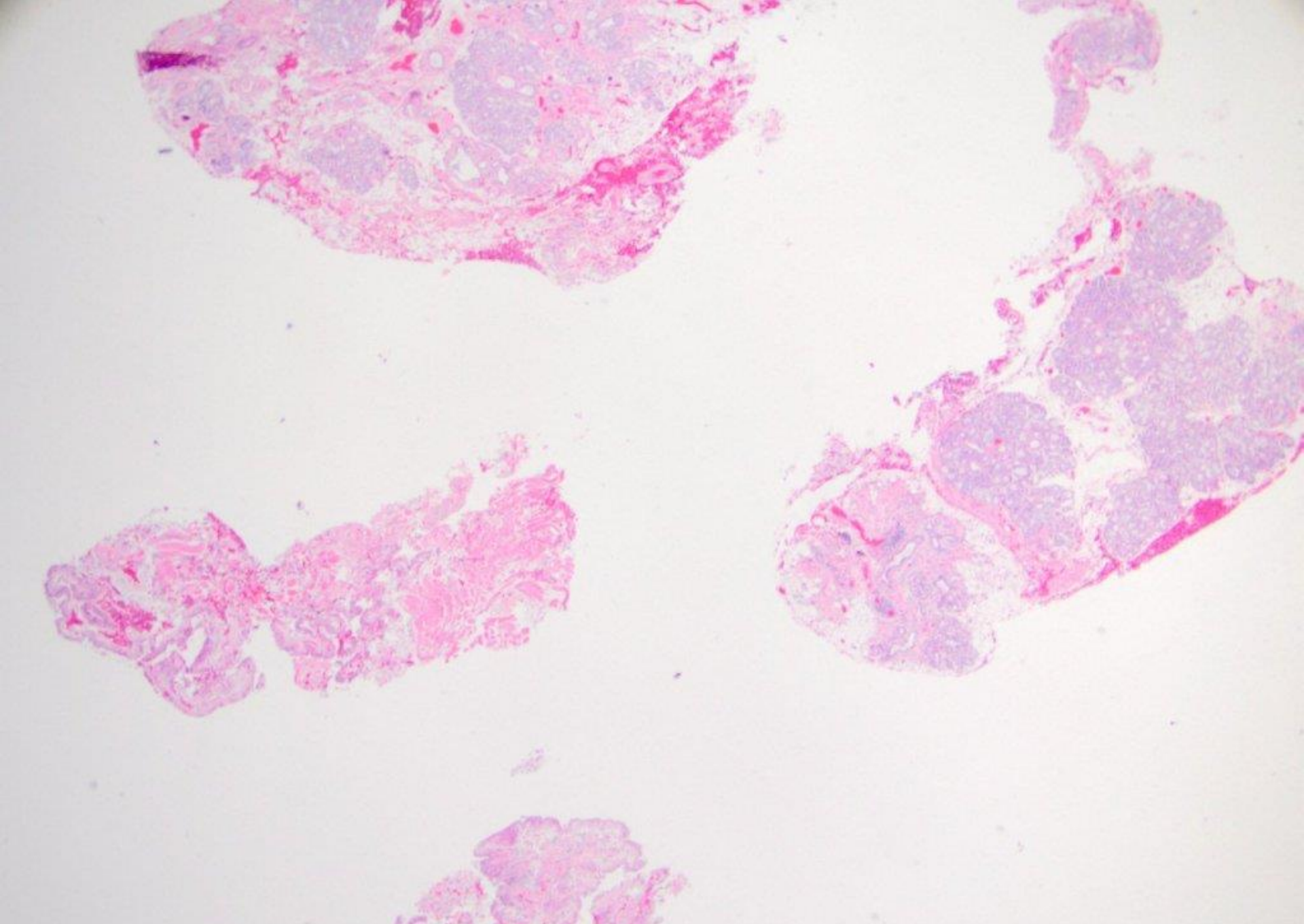


left mandible, area #22

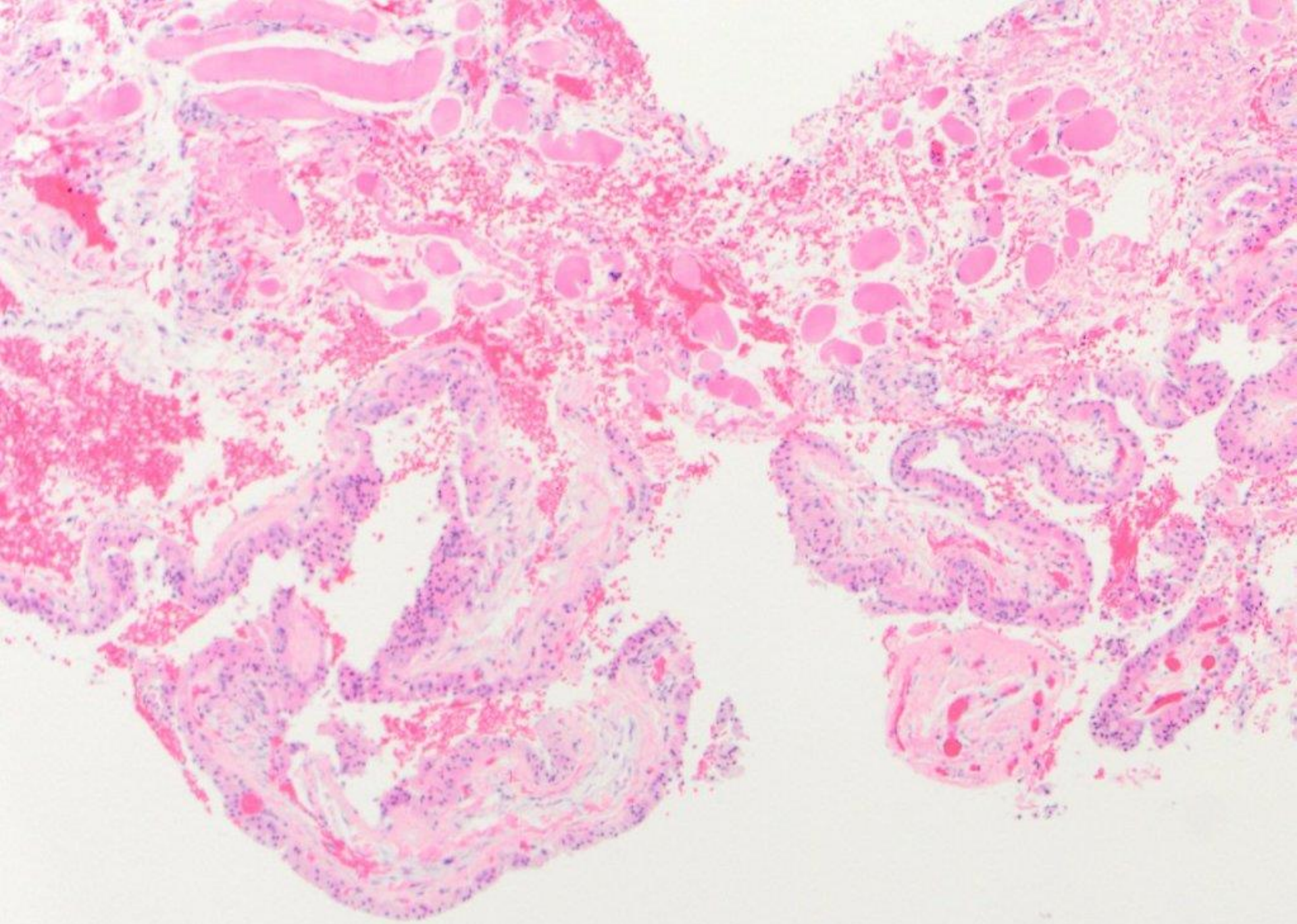


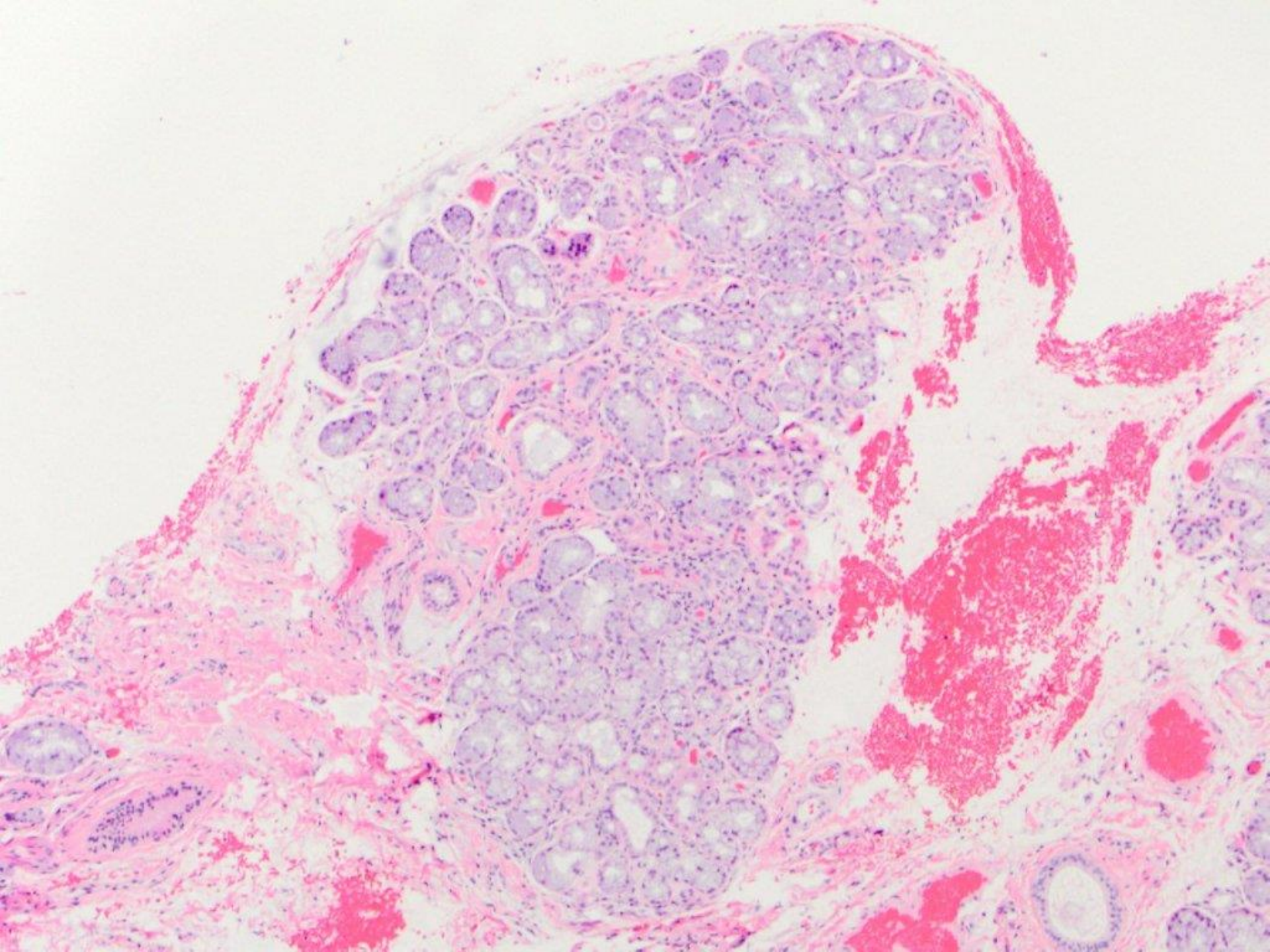


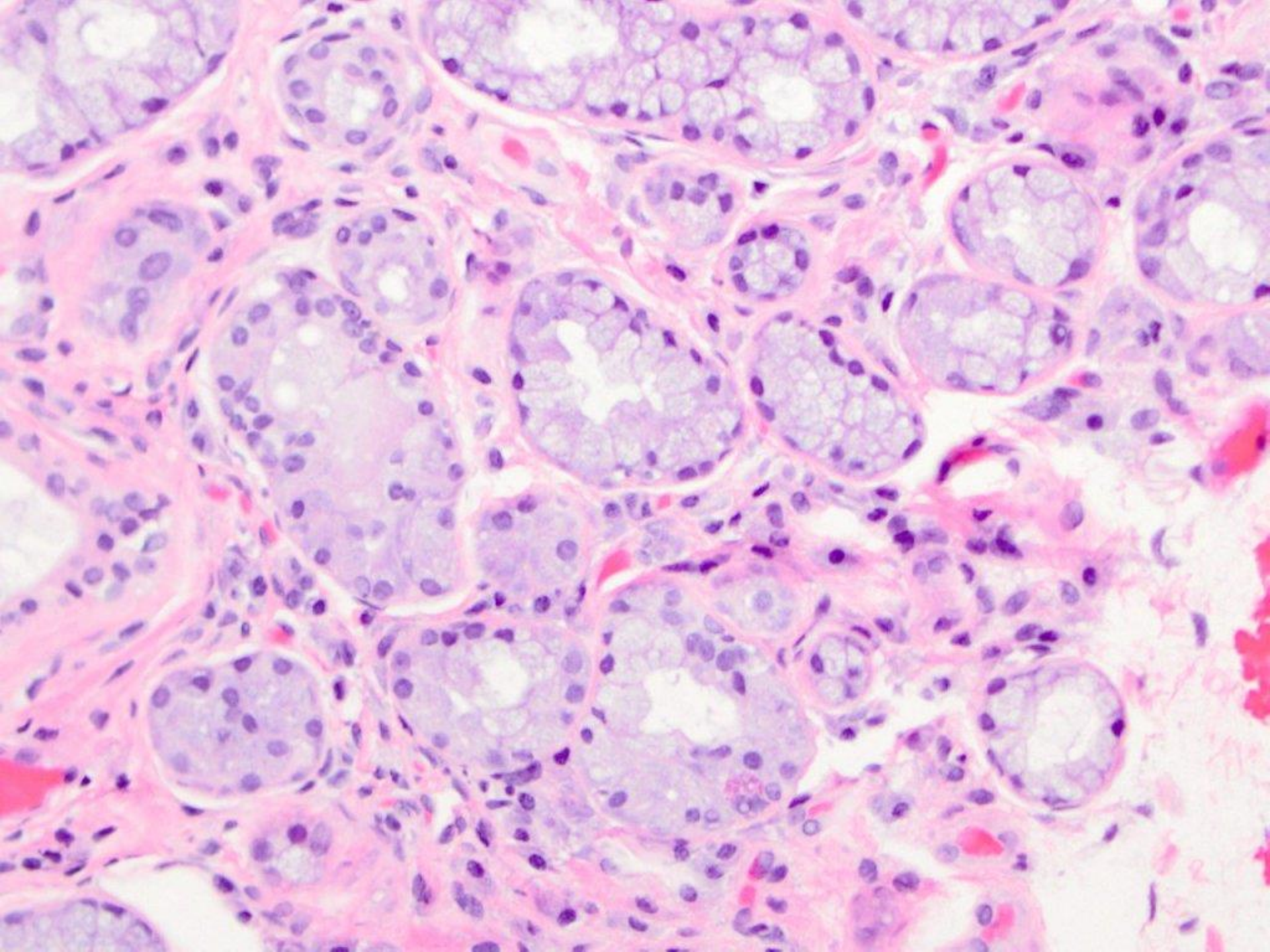
lateral periodontal cyst

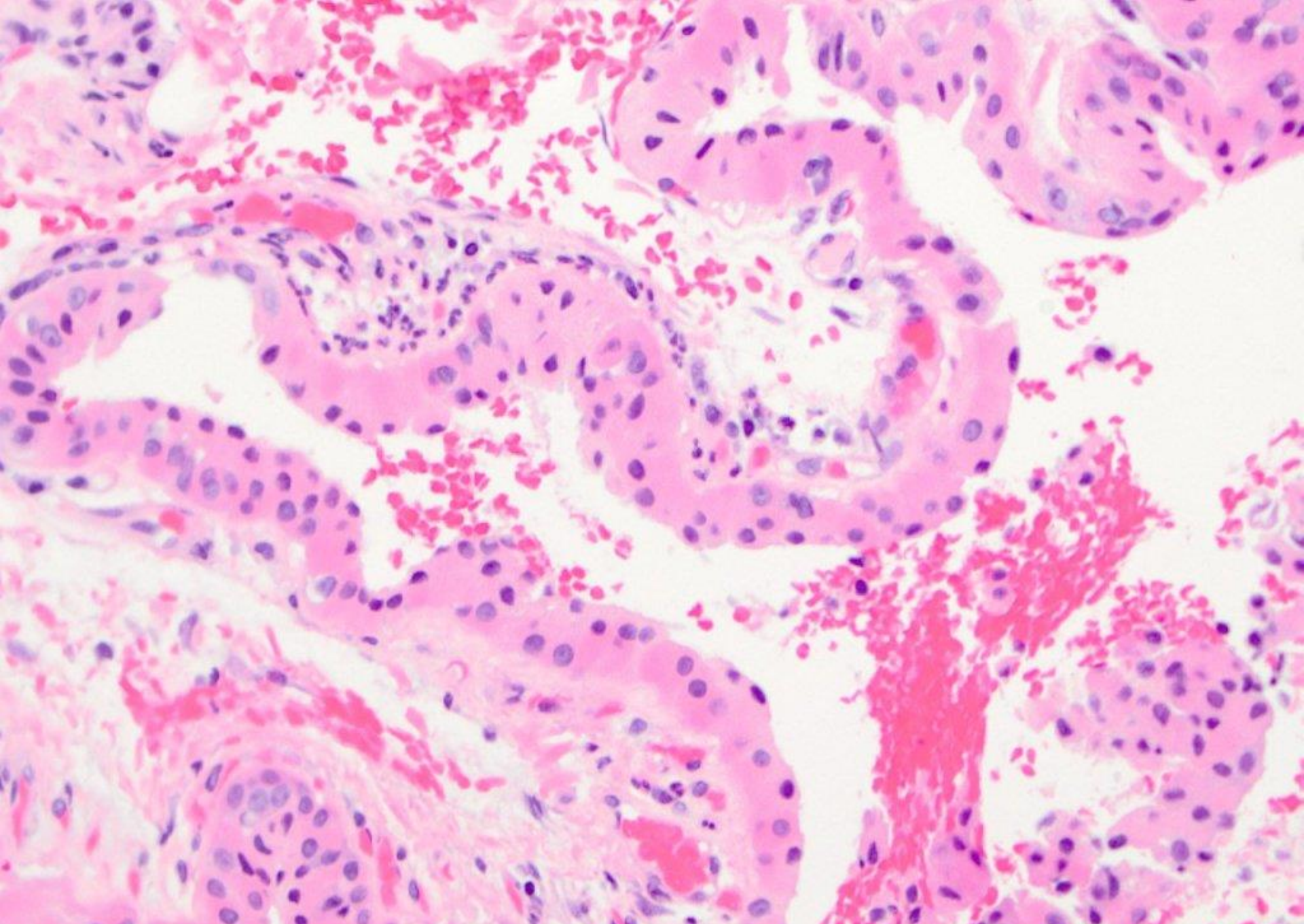


floor of mouth

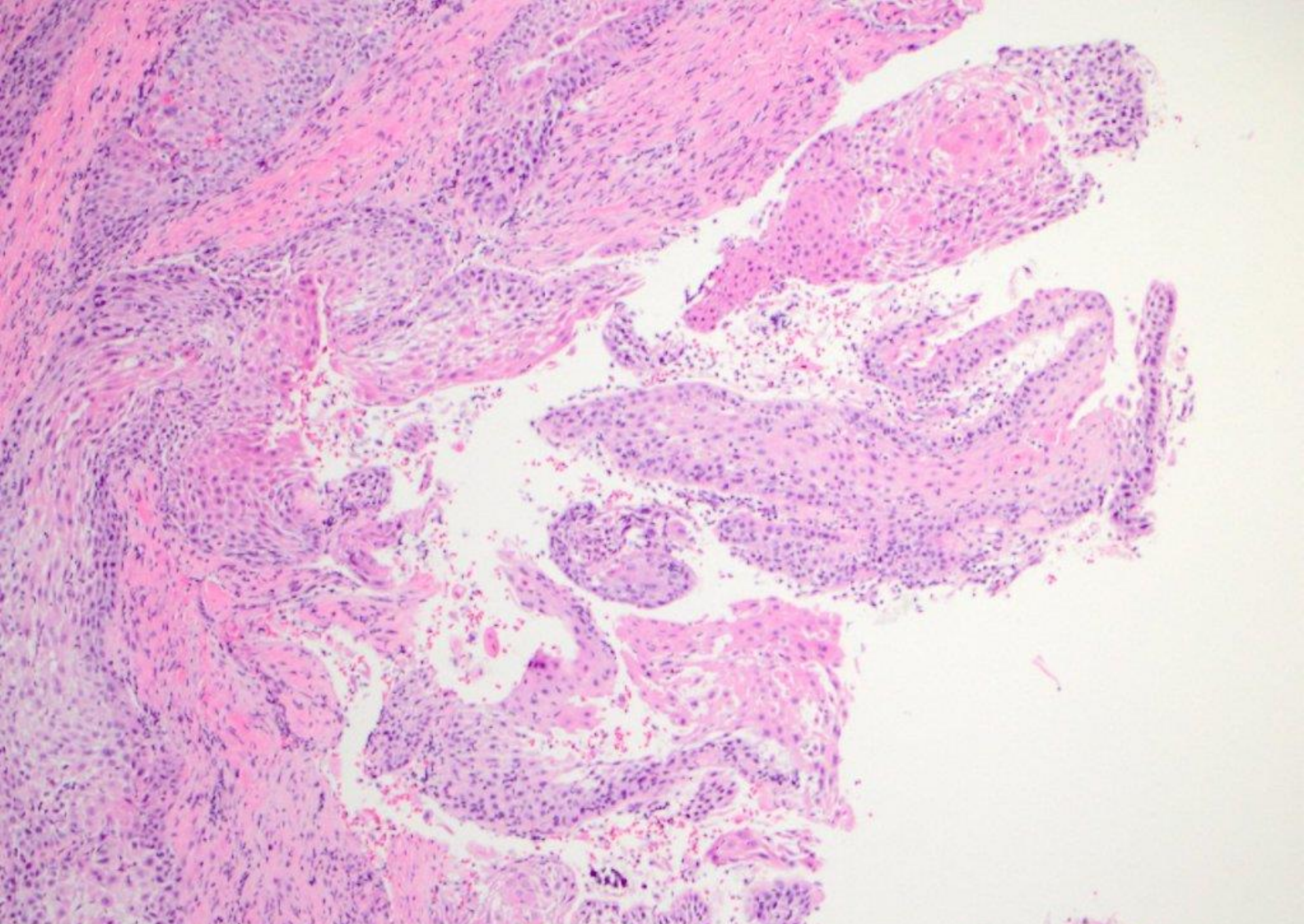




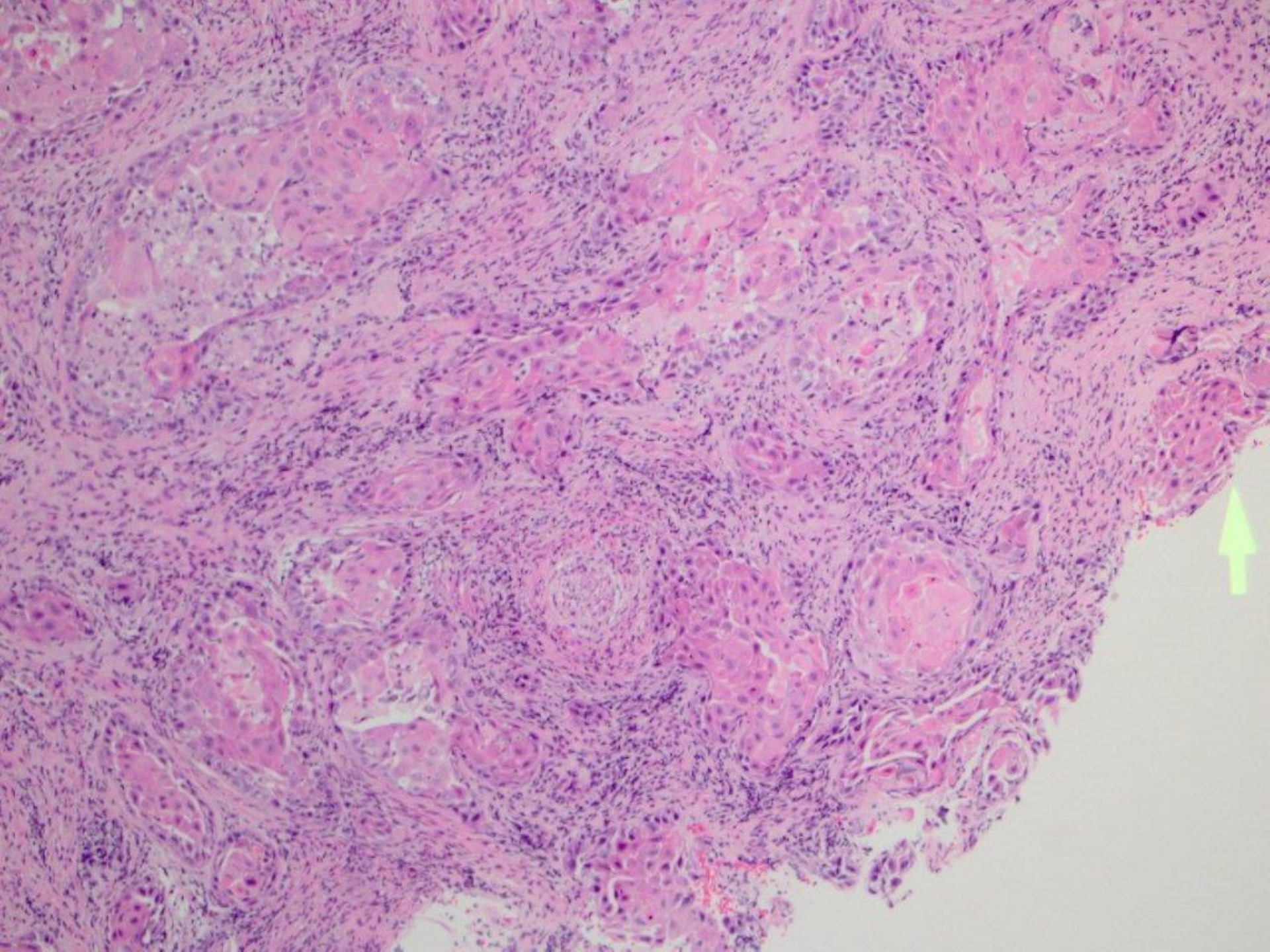


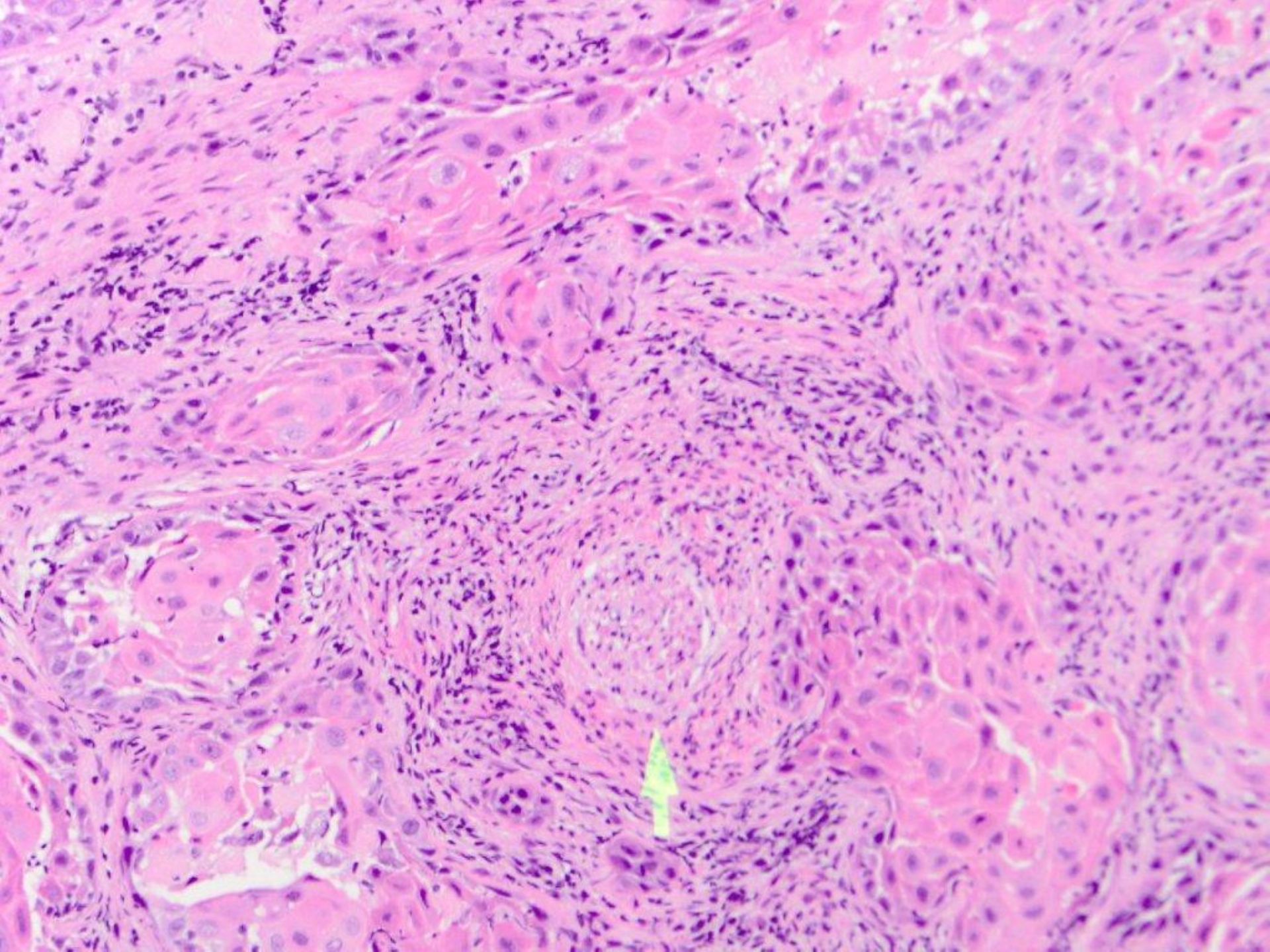


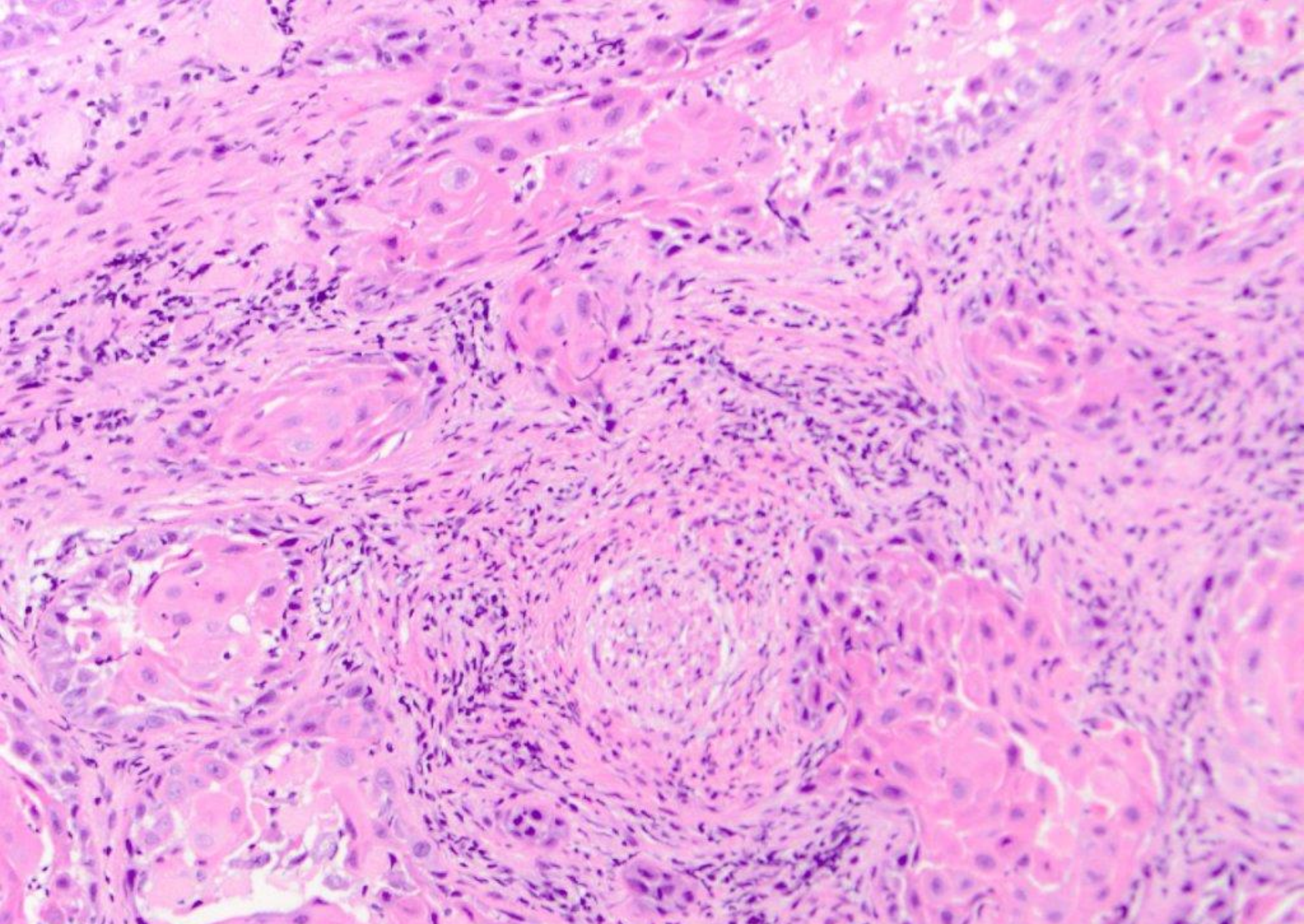
salivary duct cyst with oncocytic metaplasia



posterior mandible







(intra-osseous) squamous cell carcinoma (arising from wall of a cyst?)